Universidade do Estado do Rio de Janeiro

Centro Biomédico

Faculdade de Ciências Médicas

Hélio José Santos Bagetti Filho

Avaliação estereológica glomerular em rins de ratos após isquemia-reperfusão por clampeamento arteriovenoso e arterial

Rio de Janeiro

2012

Hélio José Santos Bagetti Filho

Avaliação estereológica glomerular em rins de ratos após isquemia-reperfusão por clampeamento arteriovenoso e arterial

Tese apresentada como requisito parcial para a obtenção do título de Doutor ao Programa de Pós-graduação em Fisiopatologia e Ciências Cirúrgicas, da Universidade do Estado do Rio de Janeiro. Área de concentração: Sistema Urogenital.

Orientador: Prof. Dr. Marco Aurélio Pereira Sampaio

Coorientador: Prof. Dr. Francisco José Barcellos Sampaio

Rio de Janeiro

2012

CATALOGAÇÃO NA FONTE
UERJ/REDE SIRIUS/BIBLIOTECA CB-A

B144 Bagetti Filho, Hélio José Santos.
Avaliação estereológica em rins de ratos submetidos à isquemia-reperfusão por clampeamento arteriovenoso e arterial / Hélio José Santos Bagetti Filho.
46 f : il.

Orientador: Marco Aurélio Pereira Sampaio.
Coorientador: Francisco José Barcellos Sampaio.
Tese (Doutorado) – Universidade do Estado do Rio de Janeiro, Faculdade de Ciências Médicas. Pós-graduação em Fisiopatologia e Ciências Cirúrgicas.

1. Rins - Cirurgia - Teses. 2. Estereologia - Teses. 3. Isquemia – Complicações e sequelas - Teses. 4. Traumatismo por reperfusão – Complicações e sequelas - Teses. 5. Circulação renal – Fisiologia - Teses. 6. Rato como animal de laboratório – Teses. 7. Ratos Wistar. I. Sampaio, Marco Aurélio Pereira. II. Sampaio, Francisco José Barcellos. III. Universidade do Estado do Rio de Janeiro. Faculdade de Ciências Médicas. IV. Título.

CDU 616.61-089

Autorizo, apenas para fins acadêmicos e científicos, a reprodução total ou parcial desta tese, desde que citada a fonte.

_____ _____

Assinatura Data

Hélio José Santos Bagetti Filho

Avaliação estereológica glomerular em rins de ratos após isquemia-reperfusão por clampeamento arteriovenoso e arterial

Tese apresentada como requisito parcial para a obtenção do título de Doutor ao Programa de Pós-graduação em Fisiopatologia e Ciências Cirúrgicas da Universidade do Estado do Rio de Janeiro. Área de concentração: Sistema Urogenital.

Aprovada em 13 de junho de 2012.

Orientador: Prof. Dr. Marco Aurélio Pereira Sampaio

Universidade Federal Fluminense

Coorientador:

Prof. Dr. Francisco José Barcellos Sampaio

Instituto de Biologia Roberto Alcântara Gomes - UERJ

Banca examinadora:

_____

Prof. Dr. Waldemar Silva Costa

Instituto de Biologia Roberto Alcântara Gomes - UERJ

_____

Prof. Dr. Diogo Benchimol de Souza

Instituto de Biologia Roberto Alcântara Gomes - UERJ

_____

Prof. Dr. Maurício Alves Chagas

Universidade Federal Fluminense

_____

Prof. Dr. Marcelo Abidu Figueiredo

Universidade Federal Rural do Rio de Janeiro

_____

Prof. Dr. Edmundo Jorge Abílio

Universidade Estadual do Norte Fluminense

Rio de Janeiro

2012

AGRADECIMENTOS

Ao professor Doutor Diogo Benchimol de Souza, pela ajuda e disponibilidade sempre que seus conhecimentos técnicos foram requisitados para a realização do projeto.

Às Médicas Veterinárias Carina Teixeira Ribeiro e Raquel Milhomem Lange, pela ajuda no processamento histológico do material, pela captura das imagens e pela coleta de dados.

Às acadêmicas de Medicina Veterinária Eloisa Cristina de Oliveira de Holanda e Nathalia Lousada Fernandes, pela ajuda nos procedimentos cirúrgicos e pelo processamento do material histológico.

À acadêmica de Medicina Ana Letícia Morais de Souza, pela ajuda durante a realização das cirurgias.

Ao professor Doutor Francisco José Barcellos Sampaio pela oportunidade de compartilhar de suas idéias, de sua experiência e de poder ter concluído este trabalho dando totais condições para que o mesmo fosse realizado integralmente dentro do Laboratório de Pesquisa Urogenital.

Ao professor Doutor Marco Aurélio Pereira Sampaio, pela orientação, motivação e inspiração.

RESUMO

BAGETTI FILHO, Hélio José Santos. *Avaliação do parênquima renal em ratos submetidos à isquemia-reperfusão após clampeamento arteriovenoso e arterial.* 2012. 46 f. Tese (Doutorado em Fisiopatologia e Ciências Cirúrgicas) – Faculdade de Ciências Médicas, Universidade do Estado do Rio de Janeiro, Rio de Janeiro, 2012.

A técnica de isquemia-reperfusão tem sido utilizada em cirurgias conservadoras do rim como a nefrectomia parcial e em transplantes renais. Para se realizar a isquemia pode-se fazer o bloqueio do fluxo sanguíneo da artéria renal ou o bloqueio simultâneo da artéria e da veia renal. O evento isquêmico acarreta em dano celular ao rim principalmente pelo estresse oxidativo local e a liberação de radicais livres assim como o aumento da resposta inflamatória. Diversos autores verificaram lesão renal após a isquemia-reperfusão, porém, apenas testes funcionais foram realizados até o momento. Os autores que tentaram avaliar a lesão morfológica do rim apenas fizeram a quantificação de escores subjetivos. O nosso objetivo é avaliar por quantificação estereológica o dano causado pela isquemia-reperfusão comparando o clampeamento somente arterial com o clampeamento arteriovenoso. Utilizamos 24 ratos wistar, machos, de quatro meses de idade. Os animais foram divididos em três grupos: o grupo Sham (n=8), o grupo de clampeamento somente da artéria renal (n=8) e o grupo de clampeamento simultâneo da artéria e da veia renal (n=8). Os animais foram submetidos a laparotomia mediana. Os animais do grupo Sham permaneceram os 60 minutos anestesiados mas sem obstrução do fluxo sanguíneo de seus vasos renais. Os animais do grupo de clampeamento arterial foram submetidos à clampeamento de sua arterial renal esquerda por 60 minutos e os animais do grupo de clampeamento arterial e venoso tiveram seus vasos renais esquerdos clampeados simultaneamente e em bloco pelo mesmo tempo. Após os 60 minutos os animais foram suturados e mantidos por 30 dias em caixas próprias sendo mortos por sobredose anestésica após decorrido esse tempo. Os rins foram coletados e mantidos em solução de formalina tamponada e posteriormente processados para análise histológica e estereológica. Foram analisados a densidade volumétrica (Vv) dos glomérulos, o número de glomérulos/mm^3(Nv) e o volume glomerular médio (VGM). A Vv e Nv se encontrou reduzida nos rins esquerdos submetidos à isquemia mas foi somente significativa nos animais do grupo de clampeamento arterial e venoso. Mesmo usando o rato como modelo animal experimental, a partir de nossos resultados recomendamos o uso do clampeamento somente arterial nos casos em que mínina lesão ao rim é imperiosa.

Palavras-chave: Estereologia. Rato. Rim. Isquemia-reperfusão.

ABSTRACT

BAGETTI FILHO, Hélio José Santos. *Assessment of the renal parenchyma in rats undergone to ischemia-reperfusion after arteriovenous and arterial clamping*. 2012. 46 f. Tese (Doutorado em Fisiopatologia e Ciências Cirúrgicas) – Faculdade de Ciências Médicas, Universidade do Estado do Rio de Janeiro, Rio de Janeiro, 2012.

The ischemia-reperfusion has been used in renal surgery such as conservative partial nephrectomy and kidney transplantation. To perform ischemia we can block the blood flow of renal artery or simultaneous blockade of the renal artery and vein. The ischemia leads to cellular damage to the kidney mainly by local oxidative stress and releasing free radicals as well as increased inflammatory response. Several authors related renal injury after ischemia-reperfusion, however; only functional tests were carried out to date. The authors attempted to evaluate the morphological lesion of the kidney using subjective scores. Our goal is assess by stereological quantification of the renal parenchyma after ischemia-reperfusion injury comparing arterial only clamping and arteriovenous clamping. We used 24 Wistar rats, males, four months old. The animals were divided into three groups: Sham group (n = 8), the group of clamping of the renal artery (n = 8) and the group of simultaneous clamping of renal artery and vein (n = 8). The animals underwent laparotomy. Sham group animals remained anesthetized for 60 minutes without blood flow obstruction of their renal vessels. The group animals underwent arterial clamping have had his left renal artery clamped for 60 minutes and the animals in the group of arterial and venous clamping had their left renal vessels clamped simultaneously for the same time. After 60 minutes the animals were sutured and kept for 30 days in their own boxes being killed by anesthetic overdose after that. The kidneys were collected and kept in formaldehyde solution and subsequently processed for histological and stereological analysis. We analyzed the volume density (Vv) of the glomeruli, the number of glomeruli/mm3 (Nv) and mean glomerular volume (MGV). The Vv and Nv was reduced in the ischemic left kidney but was only significant in animals of the group of arterial and venous clamping. Even using the rat as experimental animal model, from our results we recommend the use of arterial clamping only in cases where minimum injury to the kidney is imperative.

Keywords: Estereology. Rat. Kidney. Ischemia-reperfusion.

LISTA DE FIGURAS

Figura 1 – Abertura da cavidade abdominal do rato e identificação do hilo renal..... 15

Figura 2 – Clampeamento da artéria e da veia renal simultaneamente e em bloco..... 16

Figura 3 – Dissecção do hilo renal para identificação e isolamento da artéria renal e posterior clampeamento da mesma..... 16

Figura 4 – Fotomicrografia do córtex renal dos rins esquerdos..... 19

LISTA DE ABREVIATURAS E SIGLAS

IL-1β	interleucina 1-β
TNF-α	fator de necrose tumoral-α
NO	óxido nítrico
GS	grupo sham
GAV	grupo de isquemia arteriovenosa
GA	grupo de isquemia somente arterial
W	peso
σ	densidade do líquido
V	volume
μm	micrômetro
Vv	densidade volumétrica
VGM	volume glomerular médio
Nv	número de glomérulos por mm^3

SUMÁRIO

	INTRODUÇÃO.....	9
1	**OBJETIVO**.....	12
2	**MATERIAL E MÉTODO**.....	13
3	**RESULTADOS**.....	17
4	**DISCUSSÃO**.....	20
	CONCLUSÃO.....	23
	REFERÊNCIAS.....	24
	APÊNDICE A - Perspectivas futuras do projeto	27
	APÊNDICE B - Artigo científico publicado - A proposed new classification for the renal collecting system of cattle…….....	29
	APÊNDICE C - Artigo científico publicado online - Different from renal artery only clamping, artery and vein clamping causes a significant reduction in number of rat glomeruli during warm ischemia…….....	35
	ANEXO - Aprovação da Comissão de Ética para o cuidado e uso de animais experimentais.....	46

INTRODUÇÃO

A evolução dos conhecimentos sobre a doença renovascular (doença obstrutiva renal) começou com os trabalhos pioneiros de Goldblatt et al (1934), através da colocação de clipes nas artérias renais de cães, fornecendo novos modelos de estudo e uma maneira reproduzível de induzir hipertensão experimental, e desde então, a produção de estenose nas artérias renais tem sido realizada em diversas espécies animais (KONOPKA et al., 2007).

A técnica de isquemia/reperfusão é amplamente utilizada em cirurgia renal conservadora (SEVESO et al., 2005). A patologia oclusiva das artérias renais pode produzir dois tipos de condições clínicas diferentes e independentes: hipertensão renovascular e insuficiência renal (KONOPKA et al., 2007). A lesão provocada pela isquemia/reperfusão renal continua sendo o principal problema no período peri-operatório (PARK et al., 2008), sendo responsável frequentemente por insuficiência renal aguda (JO et al., 2006; LEE et al., 2006; ALDERLIESTEN et al., 2007) e crônica (SECIN, 2008). Além de também ser responsável pelo aumento nos índices de rejeição em transplantes renais (LEE et al., 2006; NERI et al., 2007).

Com a redução do fluxo sanguíneo, o metabolismo celular passa para a via anaeróbica; o órgão entra em disfunção, mas suas células ainda permanecem vivas (METZE, 1998). Durante a isquemia/reperfusão há dano endotelial, estresse oxidativo e aumento da resposta inflamatória, a qual resulta em lesões renais (PARK et al., 2008). A consequente liberação de radicais livres como o superóxido e a hidroxila, é um importante mecanismo de lesão celular em tecidos submetidos à isquemia e reperfusão (UNAL et al., 2002).

Vários tipos de células inflamatórias foram relatadas infiltrando o rim após a isquemia/reperfusão, os papéis dos neutrófilos e das células-T foram demonstrados em muitos estudos e os macrófagos devem contribuir com a lesão renal pela produção de uma variedade de citocinas pró-inflamatórias como o fator de necrose tumoral-α (TNF-α), interleucina-1β (IL-1β) e o interferon-γ, ou ainda, enzimas proteolíticas causando dano tecidual ou pela promoção de resposta imune pela apresentação de antígenos aos linfócitos (JO et al., 2006).

O óxido nítrico (NO) desempenha papel importante na exacerbação da doença renal nos modelos de rim remanescente por alterações hemodinâmicas, já que o bloqueio da síntese de NO foi associado com uma perda maior de células endoteliais capilares do glomérulo que predispõem o tufo capilar ao colapso e à glomeruloesclerose e perda de células endoteliais peritubulares prejudicando o envio de oxigênio aos túbulos aumentando a lesão isquêmica e

estimulando a fibrose, além de estar associada a uma resposta endotelial proliferativa reduzida (KANG et al, 2002).

A isquemia renal pode ser produzida ocluindo a artéria renal por clampeamento (SCHUMER et al., 1992; KANE et al., 2004; ALDERLIESTEN et al., 2007) ou pela oclusão simultânea, também por clampeamento, da artéria e da veia renal (UNAL et al, 2002; SHEKARRIZ et al, 2004; RUBISTEIN et al, 2005; JO et al., 2006).

O tempo de isquemia em procedimentos cirúrgicos renais em humanos varia de 12 a 40 minutos (GRASSO et al., 1999; SEVESO et al., 2005). O tempo de isquemia renal em ratos utilizados em procedimentos experimentais que avaliam o dano após o evento isquêmico tem variado de 25 a 45 minutos (SCHUMER et al., 1992; UNAL et al., 2002; JO et al., 2006; ALDERLIESTEN et al., 2007; PARK et al., 2008). O tempo de isquemia em procedimentos para produção de alterações renais secundárias à isquemia considerada severa, em ratos, é de 60 minutos (PERSY et al., 1999; YSEBAERT et al., 2000). Park et al. (2008) relataram que a recuperação após 30 minutos de isquemia renal foi completa e o tempo de 90 minutos de isquemia renal causou alta mortalidade; enquanto o tempo de 60 minutos de isquemia renal produziu necrose tubular severa, mortalidade aceitável e dano morfológico residual.

Ysebaert et al (2000), observaram em rins de ratos submetidos a 60 minutos de isquemia necrose tubular aguda nas primeiras 12 a 24 horas pós-isquemia com uma importante atividade da mieloperoxidase renal refletindo ativação de células inflamatórias de adesão (células polimorfonucleares e principalmente de macrófagos/monócitos).

Apesar de Plaine e Hinman (1965) não terem encontrado, usando o coelho como modelo animal, diferença na função renal entre as técnicas de oclusão somente arterial e de oclusão simultânea da artéria e da veia renal, outros estudos utilizando o suíno como modelo animal, demonstraram que a oclusão arterial e venosa simultânea é mais prejudicial em relação à função renal sugerindo que uma veia renal aberta, sem estar ocluída, permite a perfusão retrograda e evita a congestão venosa do rim (NEELY et al, 1959; ORVIETO et al, 2007; TRACY et al., 2010). A oclusão venosa em ratos resultou numa lesão funcional do rim mais importante quando comparada com a oclusão somente arterial (PARK et al., 2008). Esses estudos prévios avaliaram os danos secundários à isquemia-reperfusão dos rins através de testes funcionais utilizando o clampeamento arterial e arterial e venoso.

Jablonski et al (1983) realizou a avaliação morfológica dos rins de ratos submetidos à clampeamento da artéria renal direita, porém, esta foi realizada através de instituição de escores subjetivos levando-se em conta a perda da borda em escova, a necrose das células tubulares, a vacuolização celular e a perda do epitélio tubular. Konopka et al (2007), também

realizou estudo morfológico em rins de ratos submetidos à isquemia por clampeamento da artéria renal esquerda, utilizando critérios semiquantitativos analisando a ausência ou presença de colapso glomerular, ausência ou presença de hipertrofia do glomérulo, intensidade e distribuição da glomeruloesclerose, atrofia de túbulos proximais e sua distribuição e presença, ausência e distribuição de infiltrado intersticial.

Park et al (2008) comparou a lesão por isquemia-reperfusão do rim em ratos comparando o clampeamento somente da artéria renal com o clampeamento somente da veia renal, utilizando critérios semiquantitativos e analisando somente os túbulos proximais e distais para percentual de dano aos túbulos por seção e graduou a severidade ao dano tubular conferindo escores de 1 a 5.

Recentemente De Souza et al (2012) demonstrou, utilizando o suíno como modelo animal, que a densidade glomerular diminui no parênquima renal após a nefrectomia parcial laparoscópica com isquemia. Até o presente momento o número de glomérulos renais não havia sido quantificado.

1 **OBJETIVO**

O objetivo do trabalho foi avaliar quantitativamente o dano glomerular causado pelo clampeamento arterial e pelo clampeamento arteriovenoso, comparando o resultado das duas técnicas.

2 **MATERIAL E MÉTODO**

O estudo foi realizado no laboratório de Pesquisa Urogenital da Universidade Estadual do Rio de Janeiro (UERJ). Foram utilizados 24 ratos Wistar, machos, de quatro meses de idade. Os 24 animais foram acondicionados em caixas próprias para ratos, com o máximo de quatro animais acondicionados por caixa, no biotério do Laboratório de Pesquisa Urogenital, recebendo água e ração *ad libitum*. Para a realização do procedimento cirúrgico os animais foram divididos em três grupos com oito ratos em cada. Os grupos foram assim divididos: grupo sham (GS), grupo isquemia arteriovenosa (GAV) e grupo isquemia arterial (GA).

No GS os animais foram anestesiados e submetidos apenas a procedimento de laparotomia mediana pelo período de 60 minutos. Após esse período foi procedida a rafia abdominal em dois planos, muscular e cutâneo.

No GAV os animais foram anestesiados e submetidos à laparotomia mediana, afastamento de vísceras abdominais para identificação do rim esquerdo e de seu hilo (Figura 1) com clampeamento da artéria e veia renais simultaneamente, em bloco, com pinça bulldog (Figura 2) pelo período de 60 minutos. As vísceras foram cobertas com gaze embebida em soro fisiológico durante o tempo de isquemia. Ao final desse período a pinça foi retirada e observada macroscopicamente a reperfusão renal pela alteração da coloração de sua superfície. Por fim, os animais foram submetidos à rafia abdominal em dois planos assim como os animais do GS.

No GA os animais foram anestesiados e submetidos à laparotomia mediana, afastamento das vísceras abdominais e após a identificação do rim esquerdo e do seu hilo foi realizada dissecção, identificação e separação da artéria renal (Figura 3) com clampeamento desta última com pinça tipo bulldog pelo período de 60 minutos. As vísceras abdominais foram cobertas com gaze embebida em soro fisiológico durante o período de duração da isquemia. Ao final desse período foi retirada a pinça e também foi observada a reperfusão renal macroscopicamente e foi procedida a rafia abdominal como os animais dos GS e GAV.

Para o procedimento cirúrgico os animais foram mantidos em protocolo anestésico de quetamina 10% e xilazina 2% na proporção de 1:1, utilizando dosagem de 0,2 ml para cada 100g de peso, por via intramuscular. Nenhum medicamento foi dado aos animais após o procedimento cirúrgico. Esses animais retornaram para suas caixas imediatamente após a cirurgia em sala com temperatura ambiente. Após total recuperação anestésica foram realocados no biotério e mantidos com água e ração *ad libitum*.

Após 30 dias da realização do procedimento cirúrgico os animais foram mortos por sobredose anestésica com injeção intraperitoneal de tiopental. Após a morte, os animais foram submetidos à toracotomia com exposição do coração para perfusão com pressão controlada via cardíaca de solução a 10% de formaldeído tamponado. Após a formolização do animal o abdômen foi aberto para a coleta de ambos os rins que após a retirada da sua cápsula adiposa foram acondicionados por imersão em recipientes contendo também solução a 10% de formaldeído tamponado.

O volume dos rins foi calculado utilizando-se o método de Scherle onde o registro do peso (W) é dado através do deslocamento de uma solução salina isotônica pelo volume do órgão. Como a densidade (σ) da solução salina isotônica é 1,0048 e o volume (V) é obtido pela fórmula: $V=W/\sigma$, o valor do volume é semelhante ao peso ($V \approx W$). Normalmente o peso é mensurado em gramas, mas se faz a conversão para a unidade de volume onde um grama equivale a 10^3 mm^3.

A área proporcional do córtex e da medular foi calculado utilizando-se o método de Cavalieri com a utilização do software ImageJ. Os rins foram seccionados em fatias transversais de dois mm de espessura e uma superfície de cada fatia foi fotografada junto com uma régua milimetrada para posterior calibração. Através do ImageJ as imagens foram analisadas. Primeiro, calibrando-se através da régua a distância ocupada por um número determinado de pixels da imagem em milímetros. Depois da calibração foi verificada a área total da fatia e a área da região medular em cada imagem e através de subtração, calculada a área da região cortical. Através do volume obtido pelo método de Scherle foi possível calcular o volume de cada região, cortical e medular.

Fragmentos isotrópicos, uniformes e randômicos dos rins foram obtidos através do método de secção vertical. Esses fragmentos foram embebidos em parafina e após secção de fatias de 5 μm de espessura as mesmas foram coradas pelo método de hematoxilina e eosina para a verificação da densidade volumétrica (Vv) e do volume glomerular médio (VGM).

Para o cálculo da Vv a qual indica o volume ocupado pelos glomérulos no córtex de cada rim, foram analisados 25 campos histológicos obtidos de cinco diferentes secções do córtex renal, sendo esta estimada pelo método de contagem de pontos M42 onde é sobreposto à imagem a ser analisada uma grade de área quadrangular delimitada por linhas e que contém 21 pares de pontos (42 pontos) unidos por uma linha de comprimento conhecido. Os glomérulos que são tocados ou atravessados pelas linhas inferior e lateral direita são eliminados da análise. Os glomérulos restantes dentro da área quadrangular entram na avaliação e os pontos que se sobrepõem a eles são contabilizados e o Vv é dado por Pp/Pt,

onde Pp é o número de pontos que se sobrepõem aos glomérulos e Pt o número total de pontos da grade. O Vv é dado em porcentagem e através do volume cortical obtido pelo método de Scherle chega-se ao valor numérico do Vv.

O VGM foi estimado usando o método de interceptação de pontos, analisando cinco campos microscópicos por secção e cinco secções por rim. Sobre o comprimento do glomérulo interceptado pela linha de uma grade com linhas paralelas entre si, é colocada uma régua logarítmica de 32 mm de comprimento composta de uma série de 15 classes (barra de Cali). Essa grade é colocada sobre a imagem em ângulos randomicamente selecionados, sendo recalculado o ângulo para cada imagem analisada. Cada interceptação individual foi elevada ao cubo e todos os valores foram multiplicados por $\pi/3$ para se obter o VGM.

O número de glomérulos por milímetro cúbico de córtex renal (Nv) foi calculado dividindo-se o Vv pelo VGM.

Todos os animais foram pesados no dia anterior à cirurgia e três e 30 dias após a cirurgia e correlacionados com o volume renal.

Foi utilizado o software GraphPad Prism para a análise estatística. A análise de variância com o pós-teste de Bonferroni foi usado para comparação das médias dos dados estereológicos e a correlação entre o peso do animal e o volume renal foram avaliados por correlação linear. Para todas as comparações $p<0,05$ foi considerado significante.

Todo o experimento foi realizado de acordo com a legislação brasileira para uso científico de animais e foi aprovado pela Comissão de Ética para o Cuidado e Uso de Animais Experimentais da Uerj com número de protocolo CEUA/012/2012.

Figura 1 - Abertura da cavidade abdominal do rato e identificação do hilo renal

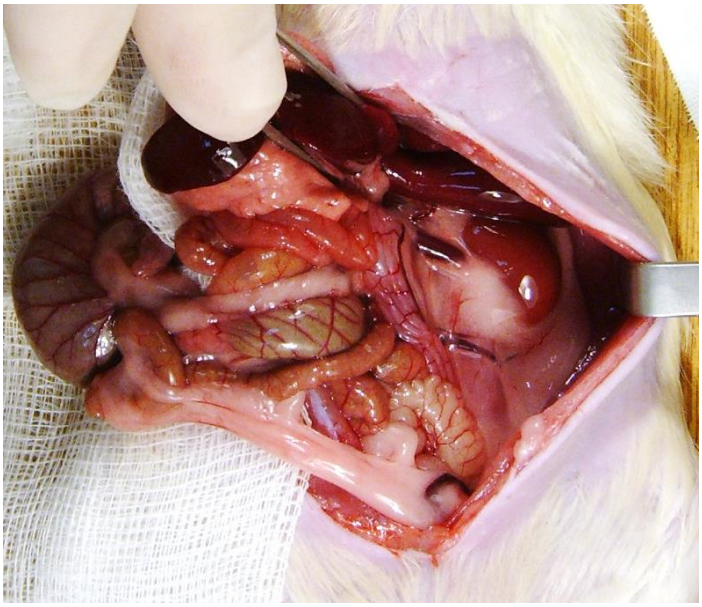

Fonte: O Autor

Figura 2 - Clampeamento da artéria e da veia renal simultaneamente e em bloco

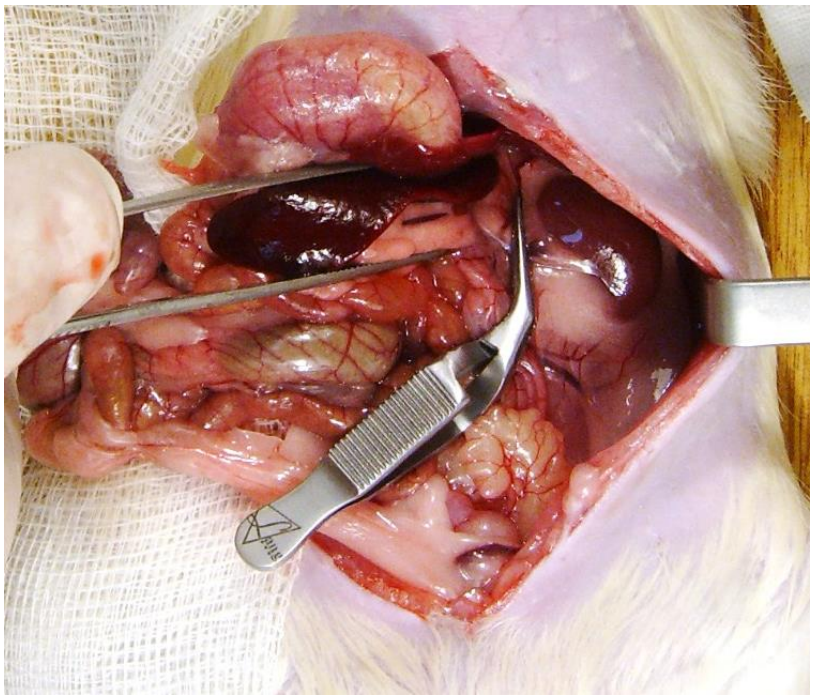

Fonte: O Autor

Figura 3: Dissecção do hilo renal para identificação e isolamento da artéria renal e posterior clampeamento da mesma.

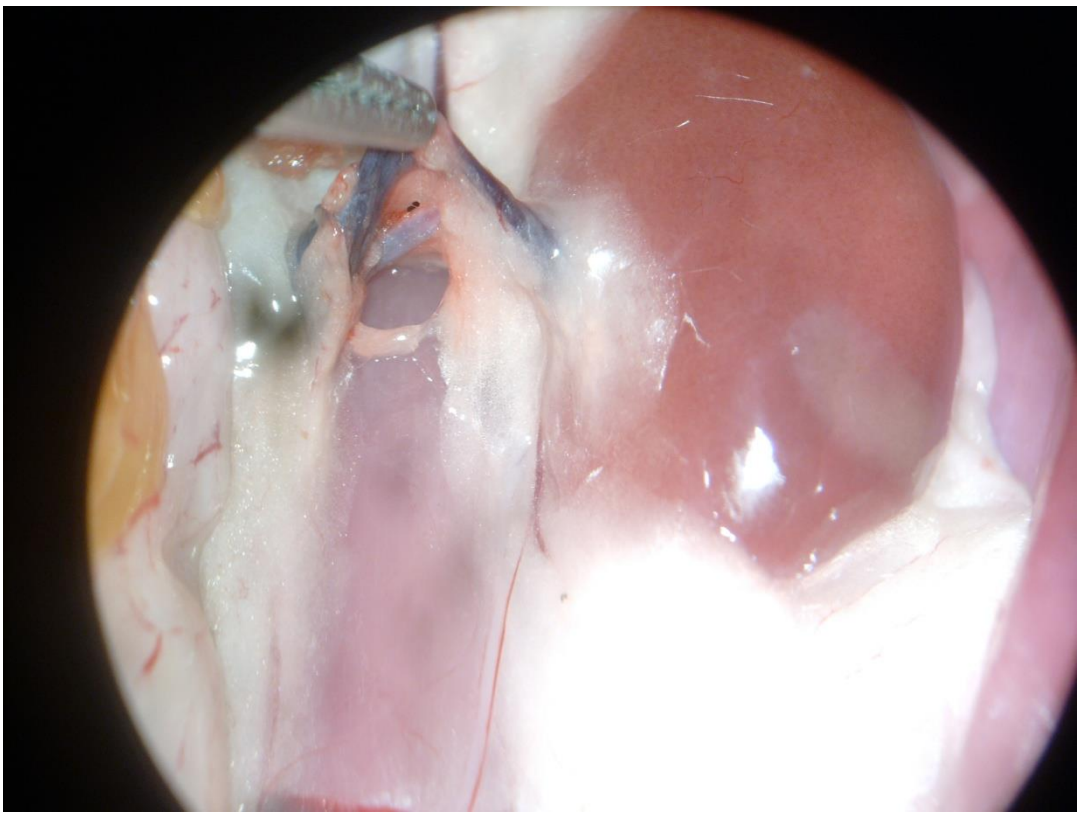

Fonte: O Autor

3 **RESULTADOS**

A Vv dos rins esquerdos nos animais do grupo GA foi de 14,65% (11,19 a 18,58), nos animais do grupo GAV foi de 12,02% (3,81 a 19,80) e a Vv dos animais do GS foi de 16,03% (8,61 a 21,86) (Figura 4). Nos rins direitos obteve-se a Vv de 16,48% (12,13 a 22,20) nos animais do grupo GA; 18,60% (15,16 a 22,49) nos animais do grupo GAV e 16,09% (8,59 a 25,41) nos animais do GS. A Vv encontrou-se reduzida nos rins esquerdos, ou seja, dos rins submetidos à isquemia quando comparados com os rins direitos nos animais submetidos a ambos os tratamentos, GA (11,1%) e GAV (35,4%). Entretanto, a diferença só foi significativa somente no grupo GAV (p=0,0074). Além disso, não houve diferença entre os rins direito e esquerdo dos animais do GS.

O Nv dos rins esquerdos dos animais do GA foi de 13,89 glomérulos/mm^3 do córtex renal (11,3 a 18,65); nos animais do grupo GAV o Nv foi de 12,34% glomérulos/mm3 do córtex renal (4,06 a 20,50) e no GS foi de 14,74 glomérulos/mm3 do córtex renal (7,15 a 19,91) . Nos rins direitos o Nv do grupo GA foi de 15,72 glomérulos/mm^3 do córtex renal (11,75 a 19,58), grupo GAV foi de 17,98 glomérulos/mm^3 do córtex renal (14,98 a 23,55). O Nv se encontra reduzido nos rins esquerdos, submetidos à isquemia, quando comparados com os rins direitos em ambos os grupos GA e GAV em 11,6% e 31,4%, respectivamente. Porém, a diferença somente foi significativa no grupo GAV (p=0,0167). Não foi encontrada diferença entre os rins direito e esquerdo nos animais do GS.

O VGM nos rins esquerdos foi de 1,07 10^3 μm^3 (0,80 a 1,34) nos animais do grupo GA; de 0,97 10^3 μm^3 (0,80 a 1,17) no grupo GAV; e foi de 1,10 10^3 μm^3 (0,85 a 1,30) no GS. Nos rins direitos o VGM foi de 1,06 10^3 μm^3 (0,77 a 1,29) nos animais do grupo GA; foi de 1,04 10^3 μm^3 (0,85 a 1,27) nos animais do grupo GAV e de 1,07 10^3 μm^3 (0,94 a 1,15) nos animais do GS. O VGM dos rins esquerdos foi semelhante quando comparados os rins direitos e esquerdos em ambos os grupos GS e GA e encontrou-se diminuído em 6,7% no grupo GAV, porém, não significante.

Tabela 1 - Dados estereológicos dos rins submetidos à isquemia arterial, isquemia arteriovenosa e do grupo sham (VGM = volume glomerular médio; Vv = densidade volumétrica; Nv = número de glomérulos/mm^3)

	Clampeamento Arterial		**Clampeamento Arterio-venoso**		**Sham**	
	Direito	**esquerdo**	**direito**	**esquerdo**	**direito**	**esquerdo**
VGM	**1.06 (± 0.16)**	**1.07 (± 0.19)**	**1.04 (± 0.12)**	**0.97 (± 0.13)**	**1.07 (± 0.09)**	**1.1 (± 0.16)**
Vv[glom]	**16.48 (± 3.28)**	**14.65 (± 2.95)**	**18.6 (± 2.82)**	**12.02 (± 5.23)**	**16.09 (± 5.77)**	**16.03 (± 4.55)**
Nv[glom]	**15.72 (± 2.62)**	**13.89 (± 3.01)**	**17.98 (± 3.2)**	**12.34 (± 4.92)**	**15.1 (± 5.72)**	**14.75 (± 4.12)**

Figura 4: Fotomicrografias do córtex renal dos rins esquerdos

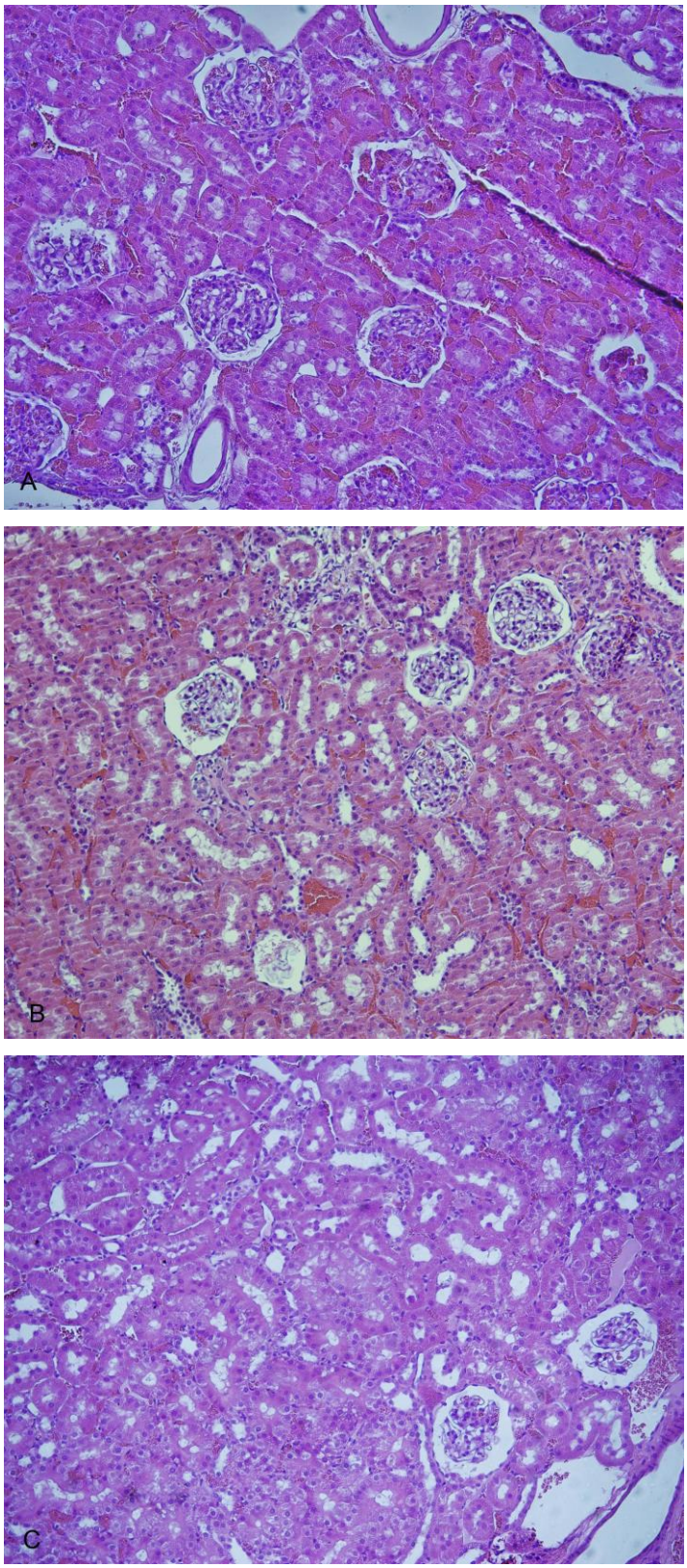

Legenda: Grupos Sham (A), Clampeamento Arterial (B) e Clampeamento Arterial e Venoso (C) onde se observa o número reduzido de glomérulos no grupo de Clampeamento Arterial e Venoso em relação aos grupos Sham e de Clampeamento arterial (aumento de 200x).

Fonte: O Autor.

4 **DISCUSSAO**

No grupo GAV, a Vv e Nv no córtex renal se encontraram significantemente reduzidos nos rins esquerdos submetidos à isquemia, quando comparados com os rins direitos que não sofreram oclusão vascular – 35,4% e 31,4%, respectivamente.

Mesmo havendo redução da Vv e do Nv nos rins esquerdos do grupo GA (11,1% e 11,6, respectivamente), as diferenças não foram significativas (p=0,2603 e 0,2147 respectivamente).

Não houve diferença entre os rins esquerdos e direitos do GS. Demonstra-se neste estudo morfológico, pela primeira vez, que a oclusão simultânea da artéria e da veia renal em ratos causou mais danos estruturais ao parênquima renal que a oclusão somente arterial.

Recentemente foi demonstrado que a oclusão arteriovenosa durante a nefrectomia parcial laparoscópica no suíno reduziu significantemente o número de glomérulos no parênquima renal (DE SOUZA et al., 2012). Porém, a limitação deste estudo se deu pela realização da nefrectomia parcial laparoscópica concomitantemente à oclusão arteriovenosa. Sendo assim, não ficou caracterizado se o dano glomerular é resultado somente da isquemia ou dos dois procedimentos em conjunto. Essa diferença é ainda mais importante quando estimado o restante do parênquima renal de uma nefrectomia parcial onde uma porção do rim foi removida.

Corpos apoptóticos podem ser encontrados nos túbulos renais distais após 5 minutos de oclusão arterial dentro de 48 horas de reperfusão em ratos. Após 30 minutos de oclusão, a apoptose se encontra em todos os túbulos renais a após 45 minutos a apoptose se encontra em todo o rim com aumento da necrose tubular (SCHUMER et al., 1992). Ysebaert et al (2000) demonstraram em ratos submetidos a 60 minutos de clampeamento arteriovenoso, que os primeiros sinais de regeneração apareceram no segundo dia de reperfusão e ao décimo dia de reperfusão metade dos túbulos proximais estava completamente regenerada. Esses achados apoiam a estimativa de que o número de glomérulos é um parâmetro mais confiável para avaliar a lesão estrutural do rim após isquemia-reperfusão, já que os túbulos lesados podem regenerar e os glomérulos não.

Assim, a diminuição no número de glomérulos sugere um dano permanente do parênquima renal (NYENGAARD et al., 1999; DE SOUZA et al., 2011).

O clampeamento arterial e arteriovenoso tem sido estudado em humanos em relação à função renal pós-operatória (GONG et al., 2008) e as alterações morfológicas também foram comparadas entre as técnicas de oclusão arterial e arteriovenosa em modelos animais

(ORVIETO et al., 2007; TRACY et al., 2010; FORMIGA et al., 2011). O clampeamento arterial parece ser menos danoso, preservando a morfologia renal. O mecanismo da prevenção do dano na oclusão arterial parece estar relacionada com o refluxo venoso, diminuindo os radicais livres e a trombose capilar e aumentando a disponibilidade de substratos para o metabolismo e oxigenação renal (TRACY et al., 2010). Formiga et al (2011), comparando o clampeamento arterial, arteriovenoso e intermitente, demonstrou que o clampeamento intermitente tem a vantagem de carrear os catabólitos do metabolismo anaeróbio e aumenta a saturação de oxigênio no tecido renal. Tracy et al (2010) demonstraram que a oxigenação tecidual é maior na oclusão arterial após 30 a 35 minutos de isquemia renal. Assim, a oxigenação do tecido renal parece ser a diferença mais importante entre os clampeamentos arterial e arteriovenoso, levando a prevenção significante de dano renal na oclusão arterial. Adiciona-se a isso ao fato de que a ativação de macrófagos e a infiltração de neutrófilos parece estar exagerada na oclusão da veia renal (PARK et al, 2008).

Uma das limitações desse estudo foi o uso do rato como modelo animal devido às diferenças anatômicas do rim humano tais como volume renal, possuir o rim unipiramidal e um sistema caliceal rudimentar. Entretanto, o uso de um modelo animal foi imperativo para a obtenção de um rim inteiro para a realização da técnica de análise estereológica. Outra limitação do nosso estudo é em relação à cirurgia, já que realizamos uma cirurgia aberta ao invés de usar a técnica laparoscópica, assim o impacto do pneumoperitônio não foi avaliado. A avaliação funcional, como o clearance de creatinina, não foram realizados, porque nós mantivemos o rim contralateral para usar como controle do rim submetido à isquemia.

A chave para uma cirurgia renal conservadora ter sucesso é a preservação do parênquima renal restante num estado de bom funcionamento. A chave para que uma nefrectomia parcial obtenha sucesso é a preservação do parênquima renal remanescente em um bom estado funcional. Assim, o uso de todas as medidas disponíveis é importante para isso. Do mesmo modo, cada paciente deve ser avaliado para a escolha do tratamento mais efetivo (RUBISTEIN et al, 2005). O tempo de clampeamento de 60 minutos de oclusão arterial não reduziu o número de glomérulos no rato. Gong et al (2008) demonstraram que o clampeamento arterial não levou a uma maior dificuldade durante a nefrectomia parcial laparoscópica, então esse método de isquemia renal deve ser considerada quando outras medidas não estão disponíveis, assim como em situações em que o resfriamento renal torna-se mais difícil, tanto pela perfusão de salina ou o uso de gelo (SHIKANOV et al, 2010). O clampeamento arterial deve também ser considerado especialmente em pacientes com função

renal previamente prejudicada. Ultimamente, entretanto, mais estudos devem ser realizados sobre o benefício do clampeamento arterial durante a nefrectomia parcial laparoscópica.

O clampeamento da artéria renal por 60 minutos não provocou dano significativo glomerular, enquanto o clampeamento arteriovenoso por 60 minutos causou uma diminuição significativa no número de glomérulos no rato. Alguns autores já haviam sugerido a utilização do clampeamento arterial para uma menor lesão renal (ORVIETO et al, 2007; GONG et al, 2008; PARK et al 2008), porém, foram utilizados testes funcionais tais como a dosagem de creatinina sérica e o clearance de creatinina e avaliação semiquantitativa conferindo-se escores subjetivos para verificar e graduar a lesão renal ou até mesmo a verificação da oxigenação renal após oclusão vascular (TRACY et al, 2010) através de técnica de diagnóstico utilizando a técnica de imagem hiperespectral gerando um mapa em tempo real da oxigenação do tecido. Nossos resultados confirmam os resultados de relatos anteriores, porém de uma forma quantitativa e demonstrando uma lesão irreversível através da verificação da perda de glomérulos. Assim, embora o experimento tenha sido realizado em modelo animal que apresenta anatomia e fisiologia diferentes do humano o clampeamento arterial deve ser recomendado quando a isquemia renal é necessária em pacientes com comprometimento prévio da função renal a fim de minimizar a injúria ao rim.

CONCLUSÃO

O clampeamento da artéria renal por 60 minutos não provocou dano significativo glomerular, enquanto o clampeamento arteriovenoso por 60 minutos causou uma diminuição significativa no número de glomérulos no rato.

REFERÊNCIAS

Alderliesten M, Graauw M, Oldenampsen J, et al. Extracellular signal-regulated kinase activation during renal ischemia/reperfusion mediates focal adhesion dissolution and renal injury. American Journal of Pathology; 171:452-462, 2007.

Andoh, T.; Gardner, M.P.; Bennett, W.M. Protective effects of dietary L-arginine supplementation on chronic cyclosporine nephrotoxicity. Experimental Transplantation, vol. 64 (9), pág. 1236-1240, 1997.

Durante, W.; Johnson, F.K.; Johnson, R.A. Arginase: a critical regulator of nitric oxide synthesis and vascular function. Clin Exp Pharmacol Physiol. 34(9) pág. 906-911. 2007.

Formiga CC, Mitre AI, Castilho LN, et al. Comparison of clamping modalities in a rabbit model of normothermic renal ischemia. Journal of Endourology; 25:1787-1791, 2011.

Gong M, Zorn KC, Orvieto MA, et al. Artery-only occlusion may provide superior renal preservation during laparoscopic partial nephrectomy. Urology; 72:843– 846.

Grasso, M; Salonia, A; Lania, C; et al. Archive Espanish Urology. 52:10, 1102-1207, 1999.

Jablonski P, Howden BO, Rae DA et al. An experimental model for assessment of renal recovery from warm ischemia. Transplantation; 35:198-204, 1983.

Jo SK, Sung SA, Cho, WY, et al. Macrophages contribute to the initiation of ischemic acute renal failure in rats. Nephrology Dialysis Transplantation; 21:1231-1239, 2006.

Kane C J, Mitchell JA, Meng MV, et al. Laparoscopic partial nephrectomy with temporary arterial occlusion: description of technique and renal functional outcomes. Urology; 63: 241–246, 2004.

Kang, DH; Nakagawa, T; Feng, A; Johnson, R. Nitric oxide modulates vascular disease in the remnant kidney model. American Journal of Pathology. Vol 161, nº 1, pág. 239-247. 2002.

Konopka, C.L.; Jurach, A.; Wender, 0.C.B. Experimental model for the study of chronic renal ischemia in rats. Morphologic, histological and ultra-structural analysis. Acta Cirúrgica Brasileira, vol. 22 (1), pág. 12-21, 2007.

Kurus, M.; Esrefoglu, M.; Bay, A.; Öztürk, F. Protective effect of oral L-arginine supplementation on cyclosporine induced nephropathy in rats. International Urology and Nephrology, 37, pág. 587-594, 2005.

Lee J, Son H, Kim M., Attenuation of ischemia-reperfusion injury by ascorbic acid in the canine renal transplantation. Journal of Veterinarian Science; 7:375-379, 2006.

Mackenzie, A.; Wadsworth, R.M. Extracellular l-arginine is required for optimal NO synthesis by eNOS and iNOS in the rat mesenteric artery wall. British Journal of Pharmacology. 139. pág. 1487-1497. 2003.

Metze, K. Distúrbios da circulação. In: Bogliolo Filho,G.B. Patologia Geral. Rio de Janeiro: Guanabara Koogan. 2ed. pág 95-99, 1998.

Neely WA and Turner MD. The effect of arterial, venous, and arteriovenous occlusion on renal blood flow. Surgery Gynecology Obstetrics; 108:669–672, 1959.

Neri F, PuvianI L, Tsivian M, et al. Protective effect of an inhibitor of interleukin-8 (meraxin) from ischemia and reperfusion injury in a rat model of kidney transplantation. Transplantation Proceedings; 39:1771-1772, 2007.

Nyengaard JR. Stereologic methods and their application in kidney research. Journal American Society of Nephrology; 10:1100-1123, 1999.

Orvieto MA, Zorn KC, Mendiola F, et al. Recovery of renal function after complete renal hilar versus artery alone clamping during open and laparoscopic surgery. Journal of Urology; 177:2371–2374, 2007.

Park, Y.; Hirose, R.; Dang, K.; Xu, F.; Behrends, M.; Tan, V.; Roberts, J.P.; Niemann, C.U. Increased severity of renal ischemiareperfusion injury with venous clamping compared to arterial clamping in a rat model. Surgery. Vol. 143, Number 2, pág. 243-251, 2008.

Persy, VP; Verstrepen, WA; Ysebaert, DK; De Greef, KE; De Broe, ME. Differences in osteopontin up-regulation between proximal and distal tubules after renal ischemia/reperfusion. Kidney International. Vol 56 (2), pág. 601-611, 1999.

Plaine LI, Hinman JR. F. Comparison of occlusion of the renal artery with occlusion of the entire pedicle on survival and serum creatinine levels of the rabbit. Journal of Urology; 93:117–121, 1965.

Rubistein M, Colombo-Junior JR; Finelli A, et al. Laparoscopic partial nephrectomy for cancer: techniques and outcomes. International Brazilina Journal of Urology, 31:100-104, 2005.

Schumer M, Colombel MC, Sawczuck IS, et al. Morphologic, biochemical and molecular evidence of apoptosis during the reperfusion phase after brief periods of renal ischemia. American Journal of Pathology; 140:831-838, 1992.

Secin, F. Importance and limits of ischemia in renal partial surgery: experimental and clinical research. Adv Urol ,Article ID 102461, 10 pages, 2008.

Seveso, M; Maugeri, O; Taverna, G;et al. Incidence and treatment of complications in nephron sparring surgery. Archive Italian Urology and Andrology. Vol 77 (4), pág. 206-210, 2005.

Shekarris B, Shah G, Upadhyay J. Impact of temporary hilar clamping during laparoscopic partial nephrectomy on postoperative renal function: a prospective study. The Journal of Urology; 172:54–57, 2004.

Shikanov S, Wille M, Large M, et al. Microparticulate ice slurry for renal hypothermia: laparoscopic partial nephrectomy in a porcine model Urology; 76:1012–1016, 2010.

Souza DB de, Oliveira LL, Cruz MC, et al. Laparoscopic partial nephrectomy under warm ischemia reduces the glomerular density in a pig model. Journal of Endourology, (in press) DOI:10.1089/end.2011.0412.

Souza DB de, Silva D, Silva MCC, et al. Effects of immobilization stress on kidneys of Wistar male rats: A morphometrical and stereological analysis. Kidney Blood Pressure Research; 34:424-429, 2011.

Tracy CR, Terrel JD, Francis RP et al. Characterization of renal ischemia using dlp hyperspectral imaging: a pilot study comparing artery-only occlusion versus artery and vein occlusion. Journal of Endourology; 24:321-325, 2010.

Unal, D. et al. Antioxidative effects of exogenous nitric oxide versus antioxidant vitamins on renal ischemia reperfusion injury. Urology Research; 30:190-194, 2002.

Ysebaert, DK; De Greef, KE; Vercauteren, SR; et al. Identification and kinetics of leukocytes after severe ischaemia/reperfusion renal injury. Nephrology Dialysis Transplantation. 15, pág. 1562-1574, 2000.

APÊNDICE A – Perspectivas futuras do projeto

A diminuição da biodisponibilidade de óxido nítrico (NO) é um mecanismo comum envolvido na patogênese de várias desordens vasculares, incluindo hipertensão, aterosclerose, diabetes e lesões de isquemia/reperfusão (DURANTE ; JOHNSON; JOHNSON, 2007).

A inibição da síntese de NO é conhecida por exacerbar a doença renal nos modelos de rim remanescente por alterações hemodinâmicas (KANG et al, 2002).

Há ampla evidência documentada dos efeitos benéficos da arginina exógena em ambos os estudos animais e clínicos e tanto a administração oral aguda como em longo prazo de L-arginina foi associada com uma significante melhora na vasodilatação dependente de NO em coelhos alimentados com colesterol, em humanos saudáveis tanto a infusão intravenosa como a administração oral induziram a vasodilatação (JOSHI et al, 2007).

MacKenzie e Wadsworth (2003) demonstraram em ratos normais, que a liberação de NO e promoção de relaxamento arterial foi obtida com aumento da concentração extracelular de L-arginina, concluindo que a alteração da concentração de L-arginina extracelular é um ponto regulador na via do NO em tecidos saudáveis o que valida a oferta racional de L-arginina em doenças arteriais.

Joshi et al (2007), demonstraram em culturas de células endoteliais que a arginina exógena pode agir como um agonista para os receptores de membrana ativando a óxido nítrico sintetase para produzir NO.

Andoh et al (1997) e Kurus et al (2005) observaram efeitos benéficos da administração oral de L-arginina em ratos tratados com ciclosporina A, presumivelmente por aumentar a produção de NO (aumentando a biossíntese de NO). Esses efeitos foram a inibição do desenvolvimento de fibrose interstício-tubular e prevenindo a diminuição da taxa de filtração glomerular.

O trabalho de Kang et al (2002) apóia a hipótese de que as alterações vasculares independentes da pressão sanguínea induzidas pelo bloqueio da NO sintetase pode ser um mecanismo adicional para a progressão da doença renal. A inibição da síntese de NO foi associada à perda significante da microvasculatura e com um prejuízo para a angiogênese local. O bloqueio de NO também foi associado com doença vascular pré-glomerular mais severa. Ambos os efeitos podem prover um mecanismo para indução de isquemia renal com a estimulação de processo de cicatrização renal.

O objetivo deste trabalho será avaliar se a suplementação com L-arginina protege de maneira significativa o parênquima renal após a isquemia-reperfusão, de forma aguda em

animais que serão mortos três dias após a cirurgia e de forma crônica no grupo que será morto após 30 dias da cirurgia.

Serão utilizados no total, quatro grupos. Dois grupos serão compostos de sete ratos wistar, cada, machos, adultos. Ambos os grupos, serão submetidos a isquemia-reperfusão durante 60 minutos clampeando-se simultaneamente sua artéria e veia renal esquerda visto que somente animais submetidos a esta técnica de clampeamento tiveram seus glomérulos significativamente diminuídos. Os vasos direitos, artéria e veia renal, serão mantidos livres para que o respectivo rim direito seja utilizado como controle. Os animais dos dois grupos receberão dose diária de 650 mg/kg de L-arginina, por via oral através de gavagem, diluída em cinco ml de solução salina a 0,9%. A gavagem dos animais ocorrerá dois dias antes, no dia do procedimento cirúrgico e dois dias após o mesmo. Um dos grupos terá seus indivíduos mortos após três dias de realização do procedimento cirúrgico e o outro grupo terá seus animais mortos 30 dias após a realização da cirurgia.

Um terceiro e quarto grupos (sham), morto três dias após e 30 dias após o procedimento cirúrgico, respectivamente, serão realizados com os animais submetidos ao mesmo tratamento dos animais dos grupos isquemia, porém, serão gavados com cinco ml de solução salina 0,9% apenas.

Todos os animais após serem mortos por sobredose anestésica de tiopental, terão seus rins coletados, armazenados em solução de formalina tamponada e processada para realização de estudo histológico e realização de estereologia para quantificação glomerular.

Esperamos verificar o efeito protetor da L-arginina sobre o parênquima renal e a possível preservação do número de glomérulos após a isquemia-reperfusão.

Andoh, T.; Gardner, M.P.; Bennett, W.M. Protective effects of dietary L-arginine supplementation on chronic cyclosporine nephrotoxicity. Experimental Transplantation, vol. 64 (9), pág. 1236-1240, 1997.

Durante, W.; Johnson, F.K.; Johnson, R.A. Arginase: a critical regulator of nitric oxide synthesis and vascular function. Clin Exp Pharmacol Physiol. 34(9) pág. 906-911. 2007.

Kurus, M.; Esrefoglu, M.; Bay, A.; Öztürk, F. Protective effect of oral L-arginine supplementation on cyclosporine induced nephropathy in rats. International Urology and Nephrology, 37, pág. 587-594, 2005.

Mackenzie, A.; Wadsworth, R.M. Extracellular l-arginine is required for optimal NO synthesis by eNOS and iNOS in the rat mesenteric artery wall. British Journal of Pharmacology. 139. pág. 1487-1497. 2003.

APÊNDICE B – Artigo científico publicado - A proposed new classification for the renal collecting system of cattle

A proposed new classification for the renal collecting system of cattle

Marco A. Pereira-Sampaio, DVM, PhD; Helio J. S. Bagetti Filho, DVM, MS; Francismar S. Carvalho, DVM; Francisco J. B. Sampaio, MD, PhD; Robert W. Henry, DVM, PhD

Objective—To evaluate the intrarenal anatomy of kidneys obtained from cattle and to propose a new classification for the renal collecting system of cattle.

Sample Population—37 kidneys from 20 adult male mixed-breed cattle.

Procedures—Intrarenal anatomy was evaluated by the use of 3-D endocasts made of the kidneys. The number of renal lobes and minor renal calyces in each kidney and each renal region (cranial pole, caudal pole, and hilus) was quantified.

Results—The renal pelvis was evident in all casts and was classified into 2 types (nondilated [28/37 {75.7%}] or dilated [9/37 {24.3%}]). All casts had a major renal calyx associated with the cranial pole and the caudal pole. The number of minor renal calices per kidney ranged from 13 to 64 (mean, 22.7). There was a significant correlation between the number of renal lobes and the number of minor renal calices for the entire kidney, the cranial pole region, and the hilus region; however, there was not a similar significant correlation for the caudal pole region. Major and minor renal calices were extremely narrow, compared with major and minor renal calices in pigs and humans.

Conclusions and Clinical Relevance—The renal collecting system of cattle, with a renal pelvis and 2 major renal calices connected to several minor renal calices by an infundibulum, differed substantially from the renal collecting system of pigs and humans. From a morphological standpoint, the kidneys of cattle were not suitable for use as a model in endourologic research and training. (*Am J Vet Res* 2010;71:1264–1269)

The renal collecting system varies among domestic mammals. The renal pelvis is a common cavity around the renal crest in dogs, cats, sheep, and goats.[1] In horses, the renal pelvis is a comparatively small central space with 2 terminal recesses extending into the renal poles.[1] Renal calices are evident in cattle and pigs, but they are absent in other domestic mammals.[1] In pigs[2] and humans,[3] a minor renal calyx surrounds the renal papilla and drains into the major renal calices, which join to form a renal pelvis. When compared with kidneys in other mammals, the kidneys of pigs and humans have differences in the morphology of the pelvicalyceal system, mainly in regard to the size and shape of the renal pelvis, with some renal pelvises lacking a dilatation.[2,3]

Received June 20, 2009.
Accepted October 26, 2009.
From the Urogenital Research Unit, State University of Rio de Janeiro, Rio de Janeiro, RJ 21941-972, Brazil (Pereira-Sampaio, Bagetti Filho, Sampaio); the Department of Morphology, Biomedical Institute, Fluminense Federal University, Niteroi, RJ 24230-220, Brazil (Pereira-Sampaio); Health Science Center, College of Veterinary Medicine, Serra dos Orgãos University Center, Teresópolis, RJ 25964-004, Brazil (Bagetti Filho, Carvalho); and the Department of Comparative Medicine, College of Veterinary Medicine, University of Tennessee, Knoxville, TN 37966 (Henry).
Supported by grants from the Foundation for Research Support of Rio de Janeiro (FAPERJ - E-26/110.419/2008), Brazil.
The authors thank Marcelo Vieira Caetano for technical assistance.
Address correspondence to Dr. Pereira-Sampaio (sampaio@vm.uff.br).

In 1 anatomy textbook,[4] the renal calices are subordinated under the renal pelvis. A similar scheme for characteristic calyceal-type kidneys is reported in another anatomy textbook.[5] However, the renal calyces are not subordinated under the renal pelvis in *Nomina Anatomica Veterinaria*,[6] which leads to confusion, especially for the note referring to cattle that states that these animals do not have a renal pelvis but instead have renal calyces. However, it does not specify whether both major and minor renal calyces are present.[6] Hence, the literature is laden with references to the presence of minor renal calyces[1,7,8] or the presence of both minor and major renal calyces.[9,10] The anatomy of the renal collecting system of cattle has generated controversial reports. In fact, there is general agreement that several minor renal calyces are present, but there are conflicting points of view regarding the existence of major renal calyces and a renal pelvis.[1,7–9,11–14] *Nomina Anatomica Veterinaria*[6] describes the renal pelvis as a dilatation at the end of the ureter and reports that the bovine kidneys have no such dilatation. Most textbooks of veterinary anatomy describe the bovine renal collecting system as lacking a renal pelvis at the end of the ureters.[1,7–9,11–13] Furthermore, some authors depict the origin of the ureter as a simple junction of 2 ureteral branches[1,7,8,12,13] or 2 major renal calyces,[9] whereas other authors[11,14] describe many major renal calyces and a tubular renal pelvis.

The kidneys of pigs are the most important renal tissues of domestic animals used for urological experi-

ments because of their similarities with the kidneys of humans.[2,15,16] Kidneys of other domestic animals, such as dogs[17–22] and rabbits,[23–26] have also been used in urological experiments. Kidneys of cattle have been used for the development of new techniques in laparoscopic partial nephrectomy.[27,28] The use of bovine kidneys in urological research and the controversial nomenclature and description of the bovine renal collecting system in the literature have stimulated interest in the study of bovine renal anatomy. Recently, the external gross anatomy was evaluated and important differences, such as kidney length and size of the renal hilus, were identified between the kidneys of adult cattle and humans.[29] However, there has not been a detailed description of the renal collecting system of cattle, which would aid understanding of the anatomy. Such a description would help researchers conduct reliable urological training. Therefore, the objective of the study reported here was to evaluate the collecting system of the kidneys of cattle and to propose a classification that would help resolve the controversy surrounding the anatomy of the bovine renal collecting system.

Materials and Methods

Sample population—Kidneys (n = 40) were collected from 20 adult male mixed-breed (Nelore X Angus) cattle (mean body weight, 480 kg; mean age, 3 years) immediately after slaughter at a slaughterhouse. All cattle underwent a clinical examination prior to slaughter, and inspections were performed during slaughter. The Institutional Animal Review Committee of the Serra dos Órgãos University Center approved the research protocol for the use of these bovine kidneys.

Procedures—A 3-D polyester resin corrosion endocast was made of the collecting system of each kidney. Casts were obtained by use of a technique described elsewhere.[2] Briefly, a cannula was inserted into the ureter. Then, 15 to 20 mL of a yellow polyester resin[a] was placed in a syringe. Methyl ethyl peroxide[b] (3% [by volume]) was added to the resin as a catalyst, and the materials were mixed. The resin mixture was manually injected via the cannula to fill the renal collecting system. All injections were performed by the same investigator (FSC). Resin was injected until the minor renal calyces could be palpated beneath the kidney surface and some resistance could be felt on the plunger of the syringe. Photographs were obtained of both surfaces of the kidney (dorsal and ventral) after the injection to record the identity of the cranial and caudal poles and the hilus region in the casts as well as the relationship between the renal lobes and the minor renal calices. The next day, the kidneys were immersed in a bath of concentrated hydrochloric acid (30%).[c] Kidneys were immersed for 48 hours to achieve total corrosion of the organic matter until only the cast of the renal collecting system remained.

Anatomic evaluation—For each kidney, the presence, shape, and size of the renal pelvis were determined at the origin of the ureter. The number of renal lobes and minor renal calyces in the entire kidney and in each renal region (cranial pole, caudal pole, and hilus) was recorded.

Statistical analysis—Differences in numbers for each variable were evaluated by use of an unpaired Student *t* test. Pearson correlations and Student *t* tests were used to estimate the linear correlation between the number of renal lobes and number of minor renal calyces. Length and thickness of the major renal calyces at the cranial and caudal poles were evaluated by use of an unpaired Student *t* test. Results were considered significant at values of $P \leq 0.05$.

Results

Three casts were not in perfect condition. There-

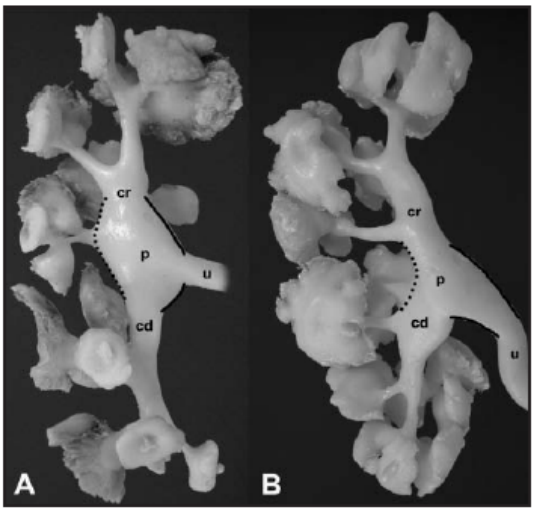

Figure 1—Dorsal photographic views of resin casts of representative renal collecting systems of adult male cattle in which the renal pelvis has a lateral border (dotted line) that is convex (A) or concave (B). The medial aspect of the dilated funnel-shaped renal pelvis (p) is indicated (solid line; A and B), which is formed by the 2 major renal calyces (1 cranial [(cr] and 1 caudal [cd]) and continues into the ureter (u).

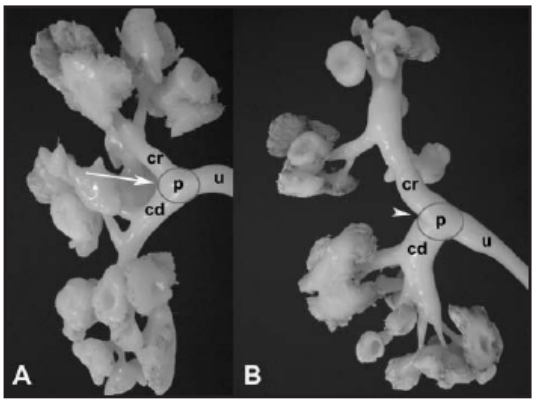

Figure 2—Dorsal photographic views of resin casts of renal collecting systems of adult male cattle. A nondilated renal pelvis (p [circle]) is formed by the major renal calyces and continues into the ureter. A—The lateral border of the renal pelvis (arrow) is concave. B—The lateral border of the renal pelvis is marked by an incisure (arrowhead) between the 2 major renal calyces. *See* Figure 1 for remainder of key.

fore, the final analysis was conducted with the remaining 37 casts.

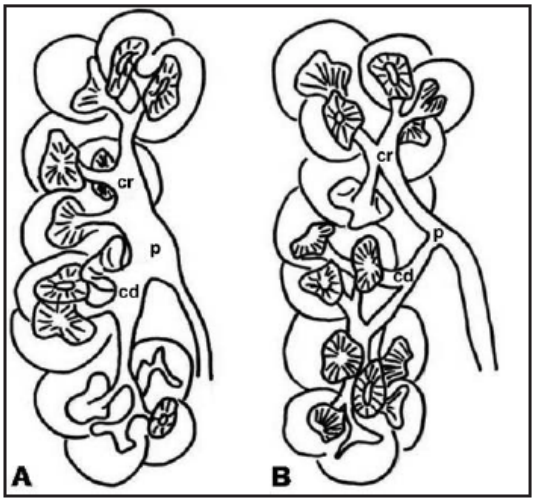

Figure 3—Schematic drawing of the 2 types of renal pelvis (dilated [A] and nondilated [B]) in bovine kidneys. *See* Figure 1 for key.

Table 1—Length and thickness of the major renal calyces at the cranial and caudal pole of 37 kidneys obtained from 20 adult male cattle.

	Length		Thickness	
Variable	**Cranial**	**Caudal**	**Cranial**	**Caudal**
Mean ± SD (mm)	35.59 ± 9.22	34.93 ± 8.92	8.53 ± 1.76	9.39 ± 2.78
CV (%)	25.91	25.54	20.63	29.61
Minimum (mm)	11.87	17.24	4.55	5.58
Maximum (mm)	54.58	60.99	12.77	19.52

CV = Coefficient of variation.

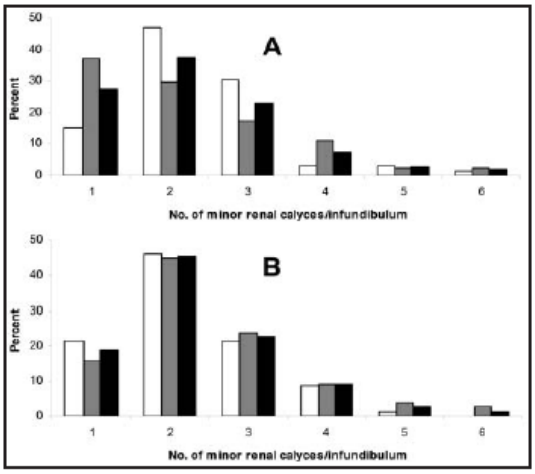

Figure 4—The number of minor renal calyces per infundibulum in the major renal calyx of the cranial pole (A) and caudal pole (B) in the right kidney (white bars), left kidney (gray bars), and both kidneys (black bars) for 37 kidneys obtained from 20 adult male cattle. The percentages were calculated from the number of infundibula with the indicated number of minor renal calyces/the total number of infundibula per indicated region.

The origin of the ureter was dilated in 9 of 37 (24.3%) casts of the renal collecting system (**Figure 1**). A dilated renal pelvis was less common (9/37 [24.3%] casts) than a nondilated renal pelvis and was represented by a large funnel-shaped cavity at the proximal end of the ureter. The lateral border of a dilated renal pelvis was either convex and bulging, caused by a branch arising from its lateral aspect, or was concave with a conical appearance.

In the remaining 28 (75.7%) casts, there was no dilatation and the origin of the ureter was formed by a funnel-like region at the union of the major renal calyces (**Figure 2**). A nondilated renal pelvis was more common (28/37 [75.7%] casts) and was represented by a small flared region in the proximal end of the ureter. The lateral border of a nondilated renal pelvis was concave or had an incisure at the junction of the 2 major renal calyces.

Therefore, a renal pelvis was present in all casts and could be classified into 2 types: nondilated and dilated (**Figure 3**).

All casts, with or without the dilated origin of the ureter, had a major renal calyx toward the cranial and the caudal poles. Length of the major renal calyx at the cranial and caudal poles ranged from 11.87 to 54.58 mm (mean, 35.59 mm) and from 17.24 to 60.99 mm (mean, 34.93 mm), respectively (**Table 1**).

The greatest thickness of the major renal calyx at the cranial and caudal poles ranged from 4.55 to 12.77 mm (mean, 8.53 mm) and from 5.58 to 19.52 mm (mean, 9.39 mm), respectively. Many minor renal calyces were connected to these 2 major renal calyces by an infundibulum; each infundibulum drained 1 to 6 minor renal calyces (**Figure 4; Table 2**).

The number of minor renal calyces per kidney ranged from 13 to 64 (mean, 22.7). The total number of minor renal calyces in each kidney and in each renal region (cranial pole, caudal pole, and hilus) was statistically analyzed (**Table 3**). Each bovine kidney had 13 to 25 renal lobes (mean, 20.6 renal lobes).

A significant correlation was detected between the number of renal lobes and the number of minor renal calyces for the entire kidney, the cranial pole region, and the hilus region (**Table 4**). However, there was not a significant correlation between the number of renal lobes and the number of minor renal calyces for the caudal pole region.

The number of renal lobes and the number of minor renal calyces differed significantly for the caudal pole region (Student *t* test, –4.41; $P = 0.005$) and the hilus region (Student *t* test, 4.47; $P = 0.002$). However, there was not a significant difference for the number of renal lobes and the number of minor renal calyces for the entire kidney (Student *t* test, –1.09; $P = 0.353$) and the cranial pole region (Student *t* test, –1.20; $P = 0.312$).

Discussion

In the study reported here, the renal pelvis was dilated in 9 of 37 (24.3%) casts. In the other 28 (75.7%)

Table 2—Number of minor renal calices per infundibulum in the cranial pole region, caudal pole region, and the entire kidney for 37 kidneys obtained from 20 adult male cattle.

No. of calyces/ infundibulum	Cranial pole			Caudal pole			Entire kidney
	Right kidney	Left kidney	Total	Right kidney	Left kidney	Total	
1	15.15 (10/66)	37.04 (30/81)	**27.21 (40/147)**	21.79 (17/78)	15.79 (12/76)	**18.83 (29/154)**	22.92 (69/301)
2	46.97 (31/66)	29.63 (24/81)	**37.41 (55/147)**	46.15 (36/78)	44.74 (34/76)	**45.45 (70/154)**	41.53 (125/301)
3	30.3 (20/66)	17.28 (14/81)	**23.13 (34/147)**	21.79 (17/78)	23.68 (18/76)	**22.73 (35/154)**	22.92 (69/301)
4	3.03 (2/66)	11.11 (9/81)	**7.48 (11/147)**	8.97 (7/78)	9.21 (7/76)	**9.09 (14/154)**	8.31 (25/301)
5	3.03 (2/66)	2.47 (2/81)	**2.72 (4/147)**	1.28 (1/78)	3.95 (3/76)	**2.6 (4/154)**	2.66 (8/301)
6	1.52 (1/66)	2.47 (2/81)	**2.04 (3/147)**	0 (0/78)	2.63 (2/76)	**1.3 (2/154)**	1.66 (5/301)

Values reported are percentages, which were calculated as the number of infundibula with the indicated number of calices/the total number of infundibula (shown in parentheses).

Table 3—Number of minor renal calices and number of renal lobes in various regions of 37 kidneys obtained from 20 adult male cattle.

Variable	Minor renal calyces				Renal lobes			
	Cranial pole	Hilus	Caudal pole	Total	Cranial pole	Hilus	Caudal pole	Total
Mean ± SD	4.43 ± 2.47	7.19 ± 3.21	11.11 ± 7.16	**22.73 ± 10.51**	3.81 ± 2.01	11.05 ± 4.26	5.76 ± 2.14	**20.62 ± 5.53**
CV (%)	55.76	44.65	64.45	**46.24**	52.76	38.55	37.15	**26.82**
Minimum	1	3	2	**13**	1	5	2	**13**
Maximum	13	17	39	**64**	9	25	12	**35**

CV = Coefficient of variation.

Table 4—Correlation between the number of renal lobes and the number of minor renal calices in various regions of 37 kidneys obtained from 20 adult male cattle.

Renal region	Equation*	*r*	*t* valve	*P* value
Cranial pole	y = 1.05x + 0.43	0.86	10.12	0.0002
Hilus	y = 0.44x + 2.38	0.58	4.28	0.0013
Caudal pole	NA	0.16	0.97	0.3856
Entire kidney	y = 1.62x – 10.75	0.85	9.63	0.0004

For each equation, y is the number of minor renal calices and x is the number of renal lobes.
NA = Not applicable.

casts, there was no noticeable dilatation of the renal pelvis. Many authors[1,7–10] describe the renal pelvis as the dilated proximal end of the ureter within the renal sinus; however, they report that the renal pelvis is absent in the kidneys of cattle. Those authors also indicate that the bovine ureter is formed by the junction of 2 ureteral branches[1,7,8] or by the junction of the major renal calyces at the cranial and caudal poles,[9,10] which differs from the results of the present study in which we identified a renal pelvis. Therefore, we propose that the renal pelvis was present in all casts and could be classified into 2 types (ie, nondilated and dilated; Figure 3). A nondilated renal pelvis was more common (28/37 [75.7%] casts) and represented a small flared region in the proximal end of the ureter. The lateral border of this type of renal pelvis was concave or had an incisure at the junction of the 2 major renal calyces (Figure 2). The lateral incisure made the lateral limit between the 2 major calyces more definitive. A dilated renal pelvis was less common (9/37 [24.3%] casts) and had a large funnel-shaped cavity at the proximal end of the ureter. The lateral border of this type of renal pelvis was convex, with a rounded appearance caused by a branch arising from it, or concave, with a conical morphological aspect (Figure 1).

In *Nomina Anatomica Veterinaria*,[6] the renal calyces are not subordinated to the renal pelvis because there is no description of a renal pelvis in cattle, at least as a dilatation at the end of the ureter. In domestic mammals and humans, the renal collecting system (ie, the renal pelvis and its subdivisions [including the renal calyces]) forms embryologically as an outgrowth of the ureteric bud. In calyceal-type kidneys, the major renal calyces subdivide into many minor renal calyces to drain the renal papilla.[5] However, there is controversy as to the presence of major renal calyces in cattle because of the numerous interpretations by different authors. This adds to the controversy concerning the presence of a renal pelvis in the bovine renal collecting system. Detailed evaluation of the renal collecting systems of pigs[2] and humans[3] revealed differences in the types of the renal pelvis.[3] In a classification of the renal collecting system in humans, investigators reported[3] various types of renal pelvis, including a small renal pelvis similar to that found in cattle in the present study. Similar to humans, the renal collecting system of pigs was evaluated and classified as a small renal pelvis[2] by the use of endocasts. Because porcine and human kidneys may have a small renal pelvis, a small renal pelvis would not be unexpected in bovine kidneys.

All casts, with or without the dilated origin of the ureter, had 2 branches (1 toward the cranial pole and 1 toward the caudal pole). These branches are considered by some authors[1,7,8] as the cranial and caudal branches of the ureter; however, to resolve the controversy, it would be more correct to consider these as major renal calyces because they drain the minor renal calyces to the renal pelvis via several branches of various sizes (Figures 1 and 2). Because the renal pelvis is evident at the origin of the ureter, it would be better to consider

the tubular extensions of the renal pelvis as major renal calyces instead of as ureteral branches because they are not connected to the ureters but instead are connected to the renal pelvis. By assigning this nomenclature to the bovine renal collecting system, confusion could be eliminated and terms could be standardized and harmonized with those of the human and porcine kidneys because the ureteric bud is developmentally responsible for this tubular system in mammals.[5] In contrast, other authors[11–14] report that the renal pelvis is located at the proximal end of the ureter, without dilatation, and is formed by 2 long cylindrical tubes that directly receive the minor renal calyces[12,13] or that receive many major renal calyces draining the minor renal calyces.[11,14] In the study reported here, minor renal calyces were connected via an infundibulum to the major renal calyces of the cranial and caudal poles. These connections have been termed major calyces by some authors,[11,14] whereas other authors[12,13] do not mention these structures and instead report that the minor renal calyces drain directly into the long ureteral branches.

Mean length of the major renal calyces associated with the cranial and caudal poles was 35.59 and 34.93 mm, respectively. The greatest mean thickness of the major renal calyces at the cranial and caudal poles was 8.53 and 9.39 mm, respectively. Minor renal calyces were connected to the 2 major calyces by an infundibulum, which drained 1 to 6 minor renal calyces. The most frequent situation was 1 infundibulum draining 2 minor renal calyces (125/301 [41.5%] infundibula), except in the cranial pole of the left kidneys, where the most common situation was 1 infundibulum draining 1 minor renal calyx (30/81 [37.0%] infundibula). In addition, the correlation between the number of renal lobes and the number of minor renal calyces has not been studied before. The number of renal lobes varied significantly among the renal areas, with the greatest number of renal lobes in the hilus region (mean, 11.1 renal lobes) and the smallest number of renal lobes in the cranial pole region (mean, 3.8 renal lobes; Table 3). We detected significant correlations between the number of renal lobes and the number of renal minor calyces in the cranial pole region, the hilus region, and the entire kidney. However, we did not detect a significant correlation between the number of renal lobes and the number of renal minor calyces in the caudal pole region.

The hilus region had significantly ($P = 0.002$) more renal lobes (11.1) than minor renal calyces (7.2). This finding is in agreement with results of other reports[12,13]; in those studies, investigators found 4 and 2 to 3 papillae/minor renal calyx, respectively. In contrast, the caudal pole had significantly ($P = 0.005$) more minor renal calyces (11.1) than renal lobes (5.8). This suggested that in the caudal pole, the cortex of the renal lobes could be fused externally, which would correspond to ≥ 1 pyramid internally.

In this study, each bovine kidney had from 13 to 64 minor renal calyces (mean, 22.7 minor renal calyces). This range differs substantially from values reported in other studies (15 to 20 minor renal calyces[12] and 18 to 24 minor renal calyces[1,11,14]). No other investigators have detected such a large number (> 30) of minor renal calyces. Furthermore, the mean number of minor renal calyces varied significantly ($P \leq 0.01$) among the renal regions, with the greatest number of minor renal calyces in the caudal pole region and the smallest number of minor renal calyces in the cranial pole region. The number of minor renal calyces in the kidneys of cattle is greater than that in the kidneys of pigs[2] (range, 4 to 19; mean, 8.2) or humans[3] (range, 5 to 14; mean, 8.2).

In the present study, major and minor renal calyces in the kidneys of cattle were extremely narrow, compared with those in pigs[2] and humans.[3] Therefore, bovine kidneys are not appropriate for use as a model in endourologic training, especially for researchers for which intrarenal access is of utmost importance (eg, in situations when researchers need to use a nephroscope).[2]

The bovine renal collecting system is variable and has 2 types of renal pelvis (dilated and nondilated). The renal pelvis has 2 major renal calyces (1 cranial and 1 caudal) that are connected to several minor renal calyces by an infundibulum. This characterization of the bovine renal collecting system is suitable for comparison with that of other domestic mammals and is an attempt to resolve the controversy regarding the presence of a renal pelvis and major renal calyces.

a. Resina polyester cristal, Resi-line Comercial ltda, Rio de Janeiro, Brazil.
b. Catalisador MEK, Resi-line Comercial ltda, Rio de Janeiro, Brazil.
c. Ácido muriático, Dipil Indústria Química, Massaranduba, Brazil.

References

1. Nickel R, Schummer A, Seiferle E, et al. Urogenital system. In: *The viscera of the domestic animals*. New York: Springer-Verlag Inc, 1973;295–298.
2. Sampaio FJB, Pereira-Sampaio MA, Favorito LA. The pig kidney as an endourological model: anatomic contribution. *J Endourol* 1998;12:45–50.
3. Sampaio FJB, Mandarim-de-Lacerda CA. Anatomic classification of the kidney collecting system for endourologic procedures. *J Endourol* 1988;2:247–251.
4. Federated Committee on Anatomical Terminology. Urinary system. In: *Terminologia anatomica*. Stuttgart, Germany: Thieme, 1998;63–64.
5. Moore KL, Persaud TVN. O sistema urogenital. In: Moore KL, Persaud TVN, eds. *Embriologia clínica*. Rio de Janeiro: Guanabara Koogan, 1994;249–283.
6. International Committee on Veterinary Gross Anatomical Nomenclature. Apparatus urogenitalis. In: *Nomina anatomica veterinaria*. 5th ed. Hannover, Germany: International Committee on Veterinary Gross Anatomical Nomenclature, 2006;62–63.
7. Dyce KM, Sack WO, Wensing CJG. Abdome dos ruminantes. In: Dyce KM, Sack WO, Wensing CJG, eds. *Tratado de anatomia veterinária*. 3rd ed. Rio de Janeiro: Elsevier, 2004;645–668.
8. König HE, Maierl J, Liebich HG. Órgãos urinários. In: König HE, Liebich HG, eds. *Anatomia dos animais domésticos*. Vol 2. Porto Alegre, Brazil: Artmed, 2004;103–118.
9. Sisson S. Aparelho urogenital do ruminante. In: Getty R, ed. *Anatomia dos animais domésticos*. Vol 1. Rio de Janeiro: Guanabara Koogan, 1986;879–880.
10. Schaller O. Organa urinaria. In: Schaller O, ed. *Nomenclatura veterinaria ilustrada*. São Paulo, Brazil: Manole, 1999;194–199.
11. Bossi V. Organi uropoietici. In: Bossi V, Caradonna GB, Spampani G, eds. *Trattato di anatomia veterinaria*. Milano, Italy: Dottor Francesco Vallardi Libro Sesto, 1909;788–815.

12. Chauveau A, Arloing S, Lesbre FX. Organi urinari. In: Chauveau A, Arloing S, Lesbre FX, eds. *Trattato di anatomia comparata degli animali domestici*. Vol 2. Torino, Italy: Editrice Torinese, 1910;84–109.
13. Montané L, Bourdelle E. Région lombaire ou abdominale supérieure. In: Montané L, Bourdelle E, eds. *Anatomie régionale des animaux domestiques*. Tome 2. Paris: Baillière et Fils, 1917;293–303.
14. Barone R. Voies D'Excrétion de L'Urine. In: *Anatomie comparée des mammiferes domestiques*. Tome 4. Paris: Editions Vigot, 2001;45–79.
15. Pereira-Sampaio MA, Favorito LA, Sampaio FJB. Pig kidney: anatomical relationships between the intrarenal arteries and the kidney collecting system. Applied study for urological research and surgical training. *J Urol* 2004;172:2077–2081.
16. Bagetti Filho HJS, Pereira-Sampaio MA, Favorito LA, et al. Pig kidney: anatomical relationships between the renal venous arrangement and the kidney collecting system. *J Urol* 2008;179:1627–1630.
17. Stephenson RA, King DK, Rohr LR. Renal cryoablation in a canine model. *Urology* 1996;47:772–776.
18. Campbell SC, Krishnamurthi V, Chow G, et al. Renal cryosurgery: experimental evaluation of treatment parameters. *Urology* 1998;52:29–34.
19. Kosieradzki M, Ametani M, Southard JH, et al. Is ischemic preconditioning of the kidney clinically relevant? *Surgery* 2003;133:81–90.
20. Sekhon CS, Sekhon BK, Singh I, et al. Attenuation of renal ischemia/reperfusion injury by a triple drug combination therapy. *J Nephrol* 2003;16:63–74.
21. Ames CD, Vanlangendonck R, Morrissey K, et al. Evaluation of surgical models for renal collecting system closure during laparoscopic partial nephrectomy. *Urology* 2005;66:451–454.
22. Mangino MJ, Ametani MS, Gilligan BJ, et al. Role of peroxynitrite anion in renal hypothermic preservation injury. *Transplantation* 2005;80:1455–1460.
23. Demirbas M, Samli M, Aksoy Y, et al. Comparison of changes in tissue oxidative-stress markers in experimental model of open, laparoscopic, and retroperitoneoscopic donor nephrectomy. *J Endourol* 2004;18:105–108.
24. Akay AF, Sahin H, Nergiz Y, et al. Reconstruction techniques in renal injury. *Saudi Med J* 2005;26:1750–1754.
25. Seckiner I, Mungan NA, Yesilli C, et al. Partial nephrectomy using a monopolar radiofrequency device: an animal model. *Urology* 2006;68:1123–1126.
26. Tyritzis SI, Kyroudi A, Liatsikos E, et al. Comparison of prolonged warm and cold ischemia on the solitary kidney during partial nephrectomy in a rabbit model. *World J Urol* 2007;25:635–640.
27. Moinzadeh A, Hasan W, Spaliviero M, et al. Water jet assisted laparoscopic partial nephrectomy without hilar clamping in the calf model. *J Urol* 2005;174:317–321.
28. Moinzadeh A, Gill IS, Rubenstein M, et al. Potassium-titanyl-phosphate laser laparoscopic partial nephrectomy without hilar clamping in the survival calf model. *J Urol* 2005;174:1110–1114.
29. Carvalho FS, Bagetti Filho HJ, Henry RW, et al. The bovine kidney as experimental model in urology: external gross anatomical contribution. *Cells Tissues Organs* 2009;190:53–58.

APÊNDICE C – Artigo científico publicado online - Different from renal artery only clamping, artery and vein clamping causes a significant reduction in number of rat glomeruli during warm ischemia

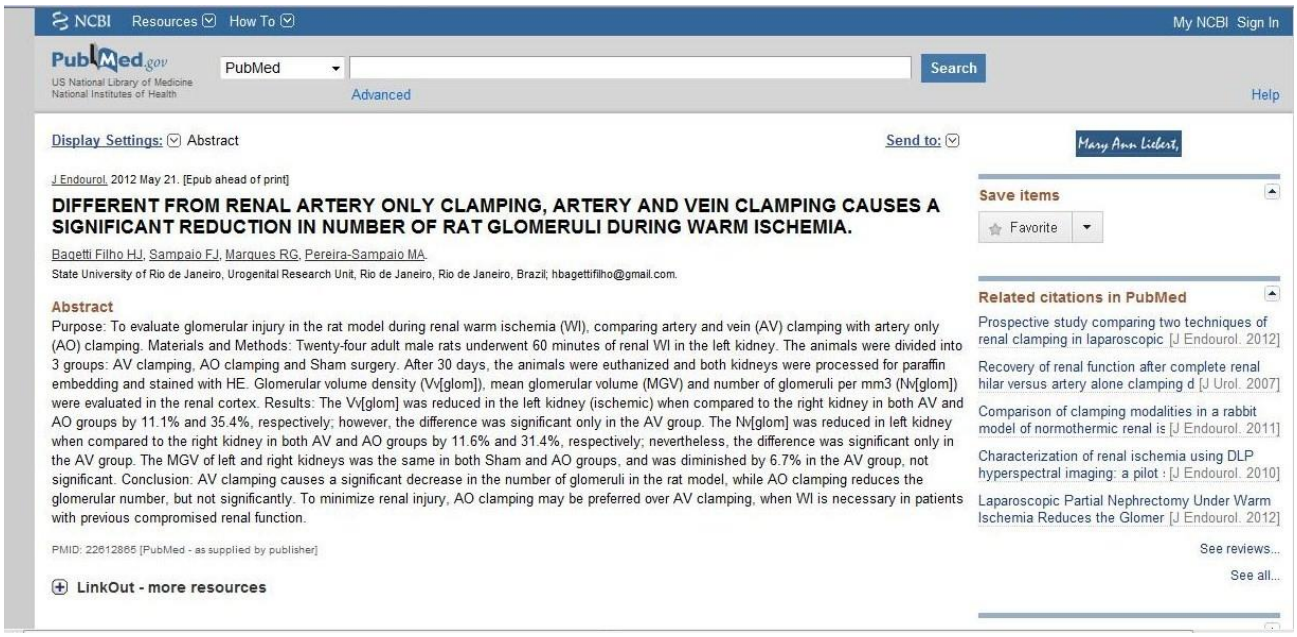
NCBI Resources How To My NCBI Sign In

PubMed.gov US National Library of Medicine National Institutes of Health

PubMed Search

Advanced Help

Display Settings: Abstract Send to:

J Endourol. 2012 May 21. [Epub ahead of print]

DIFFERENT FROM RENAL ARTERY ONLY CLAMPING, ARTERY AND VEIN CLAMPING CAUSES A SIGNIFICANT REDUCTION IN NUMBER OF RAT GLOMERULI DURING WARM ISCHEMIA.

Bagetti Filho HJ, Sampaio FJ, Marques RG, Pereira-Sampaio MA.

State University of Rio de Janeiro, Urogenital Research Unit, Rio de Janeiro, Rio de Janeiro, Brazil; hbagettifilho@gmail.com.

Abstract

Purpose: To evaluate glomerular injury in the rat model during renal warm ischemia (WI), comparing artery and vein (AV) clamping with artery only (AO) clamping. Materials and Methods: Twenty-four adult male rats underwent 60 minutes of renal WI in the left kidney. The animals were divided into 3 groups: AV clamping, AO clamping and Sham surgery. After 30 days, the animals were euthanized and both kidneys were processed for paraffin embedding and stained with HE. Glomerular volume density (Vv[glom]), mean glomerular volume (MGV) and number of glomeruli per mm3 (Nv[glom]) were evaluated in the renal cortex. Results: The Vv[glom] was reduced in the left kidney (ischemic) when compared to the right kidney in both AV and AO groups by 11.1% and 35.4%, respectively; however, the difference was significant only in the AV group. The Nv[glom] was reduced in left kidney when compared to the right kidney in both AV and AO groups by 11.6% and 31.4%, respectively; nevertheless, the difference was significant only in the AV group. The MGV of left and right kidneys was the same in both Sham and AO groups, and was diminished by 6.7% in the AV group, not significant. Conclusion: AV clamping causes a significant decrease in the number of glomeruli in the rat model, while AO clamping reduces the glomerular number, but not significantly. To minimize renal injury, AO clamping may be preferred over AV clamping, when WI is necessary in patients with previous compromised renal function.

PMID: 22612865 [PubMed - as supplied by publisher]

LinkOut - more resources

Mary Ann Liebert,

Save items

Favorite

Related citations in PubMed

Prospective study comparing two techniques of renal clamping in laparoscopic [J Endourol. 2012]

Recovery of renal function after complete renal hilar versus artery alone clamping d [J Urol. 2007]

Comparison of clamping modalities in a rabbit model of normothermic renal is [J Endourol. 2011]

Characterization of renal ischemia using DLP hyperspectral imaging: a pilot : [J Endourol. 2010]

Laparoscopic Partial Nephrectomy Under Warm Ischemia Reduces the Glomer [J Endourol. 2012]

See reviews...

See all...

DIFFERENT FROM RENAL ARTERY ONLY CLAMPING, ARTERY AND VEIN CLAMPING CAUSES A SIGNIFICANT REDUCTION IN NUMBER OF RAT GLOMERULI DURING WARM ISCHEMIA

Hélio J. S. Bagetti-Filho [1], Francisco J. B. Sampaio [1], Ruy G, Marques [2] and Marco A. Pereira-Sampaio [1,3]

1 Urogenital Research Unit, State University of Rio de Janeiro, Rio de Janeiro, RJ, Brazil.

2 Department of Surgery, State University of Rio de Janeiro, Rio de Janeiro, RJ, Brazil

3 Department of Morphology, Fluminense Federal University, Niteroi, RJ, Brazil.

Running head: RENAL ARTERY CLAMPING REDUCES GLOMERULI IN RATS

Key words: rat model, kidney, warm ischemia, artery and vein clamping, artery only clamping, stereology

(*) Correspondence address: Marco A Pereira-Sampaio. Rua Comendador Queiroz, 37/902, Icaraí, Niterói- RJ – BRAZIL. CEP 24230-220. Phone/Fax: + 55 21 26122609, e-mail: sampaio@vm.uff.br

ABSTRACT

Purpose: To evaluate glomerular injury in the rat model during renal warm ischemia (WI), comparing artery and vein (AV) clamping with artery only (AO) clamping.

Materials and Methods: Twenty-four adult male rats underwent 60 minutes of renal WI in the left kidney. The animals were divided into 3 groups: AV clamping, AO clamping and Sham surgery. After 30 days, the animals were euthanized and both kidneys were processed for paraffin embedding and stained with HE. Glomerular volume density (Vv[glom]), mean glomerular volume (MGV) and number of glomeruli per mm3 (Nv[glom]) were evaluated in the renal cortex.

Results: The Vv[glom] was reduced in the left kidney (ischemic) when compared to the right kidney in both AV and AO groups by 11.1% and 35.4%, respectively; however, the difference was significant only in the AV group. The Nv[glom] was reduced in left kidney when compared to the right kidney in both AV and AO groups by 11.6% and 31.4%, respectively; nevertheless, the difference was significant only in the AV group. The MGV of left and right kidneys was the same in both Sham and AO groups, and was diminished by 6.7% in the AV group, not significant.

Conclusion: AV clamping causes a significant decrease in the number of glomeruli in the rat model, while AO clamping reduces the glomerular number, but not significantly. To minimize renal injury, AO clamping may be preferred over AV clamping, when WI is necessary in patients with previous compromised renal function.

INTRODUCTION

Renal warm ischemia (WI) is commonly used in laparoscopic partial nephrectomy, but parenchymal damage still is the main concern during the perioperative period[1] and is the most frequent cause of chronic[2] and acute[3-5] renal failure. Renal ischemia is also responsible for an increased risk of rejection in renal transplantation.[5,6]

Ischemia-reperfusion causes endothelial damage, oxidative stress and increased inflammatory response, which leads to several renal injuries.[1] The release of free radicals, as superoxide and hydroxyl, is an important mechanism of cell injury in tissues subjected to ischemia-reperfusion.[7] Mechanisms of protection of ischemic renal injury are of utmost importance to better outcomes in nephron sparing surgery.[2]

Renal WI can be performed using artery only (AO) clamping[3,8,9] or artery and venous (AV) clamping together.[4,7,10,11] Although Plaine and Hinman[12] found no difference in renal function between AO and AV occlusion in rabbits, other studies in the porcine model demonstrated that the AV occlusion is more harmful for renal function, suggesting that the open renal vein enables retrograde perfusion and avoids venous congestion of the kidney.[13-15] Renal vein only occlusion in rats resulted in a more severe functional injury than AO occlusion.[1] However, these studies used only functional tests to assess the effects of warm ischemia during AO and AV clamping. The morphological evaluation was performed by subjective scores, usually considering brush border loss, tubular cell necrosis, cellular vacuolation and tubular epithelial loss.[16] Until now, the renal parenchyma was not quantified in order to evaluate the real and long term damage caused by AO compared to AV clamping. Recently, it was demonstrated in the porcine model that the glomerular density decreases in the remaining renal parenchyma after laparoscopic partial nephrectomy.[17]

Mean time of AO occlusion of 43 minutes during LPN seems to have no negative effect on renal function, challenging traditional concepts of maximum renal ischemia of 30 minutes. Despite these encouraging results, these studies also evaluated the renal function using nuclear renography and serum creatinine analysis.[9] Renal WI of 25 to 45 minutes has been used in several experiments to assess the renal damage in rats.[1,3,4,7,8] However, Park and colleagues[1] reported that recovery after 30 minutes of renal ischemia was complete and 90 minutes of ischemia caused high mortality; while 60 minutes of renal ischemia produced severe renal tubular necrosis, acceptable mortality and residual morphological damage.

The aim of this study was to evaluate, by using unbiased stereological methods, the effects of two methodologies of vascular clamping (artery only vs artery and vein) in a rat model after 60 minutes of renal warm ischemia (WI).

MATERIALS AND METHODS

Twenty four male Wistar rats, 4 months old were used. They were divided into 3 groups of 8: 1. Artery only (AO) clamping, 2. Artery and vein (AV) both clamped and 3. Shem (S) operated.

The rats were anesthetized via intramuscular ketamine 100 mg/kg and xylazine 20 mg/kg, prepped for surgery, and a ventral midline incision was used to expose the abdominal contents which were displaced to the right side. The left renal artery and vein were isolated. One of the three procedures (AO, AV, S) was performed: AO – the renal artery was occluded with a bulldog clamp for 60 minutes; AV – the renal artery and vein en bloc were clamped for 60 minutes; or Sham – vessels were isolated, but no clamp was applied. The abdominal contents were replaced and the incision was covered with moistened gauze during the ischemic period. At the end of the ischemic period (60 minutes), the clamps were removed and reperfusion was observed. Finally, the abdominal wall was closed.

All experiments were performed according to the National law for scientific use of animals, and this project was formally approved by the local Ethics Committee for animal experimentation.

All animals were euthanized 30 days after surgery by intravenous injection of a high dose of pentobarbital. Both left and right kidneys were harvested and fixed in 10% buffered formaldehyde. Renal volume was estimated by the Scherle's method[18] and the proportional area of the cortex and medulla was calculated by the Cavalieri's method[19] using Image-J software. Random samples from all 48 kidneys were processed for paraffin embedding, sectioned at 5μm thickness, and stained with hematoxylin & eosin. From each kidney, 25 histological fields obtained from 5 different sections of the renal cortex were examined. Glomerular volume density (Vv[glom]), which indicates the volume occupied by the glomeruli in the cortex, was estimated by the point-counting method.[19]

The mean glomerular volume (MGV) was estimated by using the "point-sampled intercepts method",[19] analyzing 5 microscopic fields per section and 5 sections per kidney. Randomly, crossed glomerular length was performed with a 32-mm long logarithmic ruler composed of a series of 15 classes. Each individual intercept was cubed, and the mean of all values was multiplied by $\pi/3$ in every case to obtain the MGV.[20]

The number of glomeruli per cubic millimeter of renal cortex (Nv[glom]), was calculated by dividing the Vv[glom] by the MGV.

Animals were weighed one day before surgery, on postoperative days 3 and 30 and correlated with the renal volume.

The analysis of variance with Bonferroni[21] post-test was used for stereological data mean comparisons. Animal weight and renal volume correlation was assessed by linear correlation. For all comparisons, $p<0.05$ was considered significant. The analyses were performed using GraphPad Prism software.

RESULTS

The AO Vv[glom] was 14.65% (range 11.19 to 18.58); the AV Vv[glom] was 12.02% (range 3.81 to 19.80); and the S Vv[glom] was 16.03% (range 8.61 to 21.86) in left kidneys. In right kidneys: the AO Vv[glom] was 16.48% (range 12.13 to 22.20); the AV Vv[glom] was 18.60% (range 15.16 to 22.49); and the S Vv[glom] was 16.09% (range 8.59 to 25.41). The Vv[glom] was reduced in left kidneys (ischemic) when compared with right kidneys in both AO and AV groups by 11.1% and 35.4%, respectively; however, the difference was significant only in AV ($p = 0.0074$). Furthermore, there was no difference between left and right kidneys from the Sham group (Fig. 1).

The AO Nv[glom] was 13.89 glomeruli/mm^3 of renal cortex (range 11.13 to 18.65); the AV Nv[glom] was 12.34 glomeruli/mm^3 of renal cortex (range 4.06 to 20.50); and the S Nv[glom] was 14.74 glomeruli/mm^3 of renal cortex (range 7.15 to 19.91) in left kidneys. In right kidneys: the AO Nv[glom] was 15.72 glomeruli/mm^3 of renal cortex (range 11.75 to 19.58); the AV Nv[glom] was 17.98 glomeruli/mm^3 of renal cortex (range 14.98 to 22.92); and the S Nv[glom] was 15.10 glomeruli/mm^3 of renal cortex (range 9.09 to 23.55). The Nv[glom] was reduced in left kidneys (ischemic) when compared with right kidneys in both AO and AV groups by 11.6% and 31.4%, respectively; nevertheless, the difference was significant only in AV ($p = 0.0167$) (Fig. 2). Moreover, there was no difference between left and right kidneys from the Sham group (Fig. 1).

The AO MGV was 1.07 $10^3 \mu m^3$ (range 0.80 to 1.34); the AV MGV was 0.97 $10^3 \mu m^3$ (range 0.80 to 1.17); and the S MGV was 1.10 $10^3 \mu m^3$ (range 0.85 to 1.30) in left kidneys. In right kidneys: the AO MGV was 1.06 $10^3 \mu m^3$ (range 0.77 to 1.29); the AV MGV was 1.04 $10^3 \mu m^3$ (range 0.85 to 1.27); and the S MGV was 1.07 $10^3 \mu m^3$ (range 0.94 to 1.15). The MGV of left kidneys was almost the same of the right kidneys in both Sham and AO groups, and diminished by 6.7% in AV group, not significant (Table 1).

DISCUSSION

Despite the advanced development of laparoscopic partial nephrectomy (LPN) techniques, which can mimic almost completely the open surgery,[22] renal cooling techniques to minimize renal damage by warm ischemia are not easily performed during laparoscopic surgery.[23] Recently, ice-slurry has been tested in a porcine model for renal hypothermia during LPN, but it has still not gained clinical acceptance.[24] Bleeding control during renal surgery can be accomplished by several ways, but vascular occlusion is still very important

for reducing bleeding in the surgical field, enabling accurate tumor resection and precise collecting system closure.[25] However, vascular occlusion results in a transient period of warm ischemia that may affect renal function.[2]

Since the main purpose of conservative renal surgery is to preserve the largest number of nephrons and as the glomeruli can not be produced after birth, an objective evaluation of the number of glomeruli after the WI is of great importance to compare AO and AV occlusion. Such is the unbiased stereological method used in this study, which can accurately estimate the number of glomeruli in the kidney.[19]

In the current study, glomerular volume density (Vv[glom]) and glomerular number (Nv[glom]) in the renal cortex were significantly reduced in left (ischemic) kidneys when compared with right (nonoccluded) kidneys of AV groups by 35.4% and 31.4%, respectively. Even though there was reduction of Vv[glom] and Nv[glom] in AO left kidneys (11.1% and 11.6% respectively), the differences was not significant ($p = 0.2603$ and 0.2147 respectively). Furthermore, there was no difference between left and right kidneys from the Sham group (Fig. 1). To our knowledge, the present morphological study demonstrated for the first time that the AV clamping caused more structural damage in the renal parenchyma than the AO clamping in rats. Recently, it was demonstrated that the AV occlusion during LPN in a porcine model significantly reduced the number of glomeruli in the renal parenchyma.[17] This difference is more important when estimated for the remaining parenchyma of a partial nephrectomy, where a portion of the kidney has been removed.

Apoptotic bodies can be found in the distal renal tubules after 5 minutes of AO occlusion within 48 hours of reperfusion in rats. After 30 minutes of occlusion, the apoptosis spreads for all renal tubules and after 45 minutes the apoptosis spreads throughout the kidney with increasing of tubular necrosis.[8] Ysebaert and colleagues[27] demonstrated in rats submitted to 60 minutes of AV clamping, that the first signs of regeneration appeared at the second day of reperfusion and at the 10th day of reperfusion, half of the proximal tubules were completely regenerated. These findings support the estimating of glomerular number as a more reliable parameter for assessing the structural renal injury after ischemia/reperfusion, since the tubular injury can regenerate, while glomeruli will not regenerate. Therefore, the decreasing of the glomerular number suggests a permanent damage of the renal parenchyma.[28,29]

AO and AV clamping have been studied in humans with regard to postoperative renal function[30] and the morphological changes are also compared between AO and AV occlusion in animal models.[13,15,26] The AO clamping seemed to be less hazardous, preserving the renal

morphology. The mechanism of damage prevention in the AO occlusion seems to be related with the venous backflow, decreasing free radicals and capillary thrombosis, and increasing availability of substrate for metabolism and renal oxygenation.[13] Formiga and colleagues,[26] comparing AO, AV and intermittent occlusion, demonstrated that the intermittent clamping has the advantage of washing out catabolites from anaerobic metabolism and increase the oxygen saturation in the renal tissue. Tracy and collaborators,[13] shown that the tissue oxygenation is higher in AO occlusion, after 30 to 35 minutes of warm ischemia. Therefore, the oxygenation of the renal tissue seems to be the most important difference between the AO and AV occlusion, leading to a significant prevention of renal damage in the AO occlusion.

One of the limitations of this study is the use of a rat model, due to the anatomical differences from human kidneys, such as renal volume, unipapillary kidney and rudimentar caliceal system. However, the use of an animal model was imperative to obtain the entire kidney for performing the technique of stereological analysis. Another limitation of the study is regard to surgery, because we perform an open surgery instead of laparoscopic approach, so the impact of the pneumoperitoneum was not assessed. Functional evaluation, as a creatinine clearance, was not used, because we kept the contralateral kidney to use as a control for the kidney that underwent ischemia.

The key to a successful nephron sparing surgery is the preservation of the remaining parenchyma in good functional status. Thereby, the use of all available measures is important for this. Likewise, each patient must be evaluated to choose the most effective treatment.[10] The AO occlusion for 60 minutes did not reduce the number of glomeruli in the rat model. Gong and colleagues[30] demonstrated that the AO clamping did not lead to higher difficulty during LPN, then this method of ischemia should be considered when other measures are unavailable, as well as in situations that make the renal cooling difficult, either by perfusion of saline or use of ice-slurry.[24] The AO clamping must also be considered especially in patients with prior impaired renal function. Ultimately, however, more studies should be performed regarding the benefit of AO clamping during LPN.

In conclusion, the AO clamping for 60 minutes does not cause significant glomerular damage, while the AV clamping for 60 minutes causes a significant decrease in the number of glomeruli in the rat model. Thus, the AO clamping could be recommended when WI is necessary or in patients with previous compromised renal function, to minimize renal injury.

ACKNOWLEDGMENTS

This study was supported by grants from the National Council of Scientific and Technological Development (CNPq) and Foundation for Research Support of Rio de Janeiro (FAPERJ), BRAZIL.

DISCLOSURE STATEMENT

No competing financial interests exist.

REFERENCES

1. Park Y, Hirose R, Dang K, et al. Increased severity of renal ischemia-reperfusion injury with venous clamping compared to arterial clamping in a rat model. Surgery 2008; 143:243-251.

2. Secin F. Importance and limits of ischemia in renal partial surgery: experimental and clinical research. Adv Urol 2008; Article ID 102461, 10 pages.

3. Alderliesten M, Graauw M, Oldenampsen, J, et al. Extracellular signal-regulated kinase activation during renal ischemia/reperfusion mediates focal adhesion dissolution and renal injury. Am J Pathol 2007; 171:452-462.

4. Jo SK, Sung SA, Cho, WY, et al. Macrophages contribute to the initiation of ischemic acute renal failure in rats. Nephrol Dial Transplant 2006; 21:1231-1239.

5. Lee J, Son H, Kim M., Attenuation of ischemia-reperfusion injury by ascorbic acid in the canine renal transplantation. J Vet Sci 2006; 7:375-379.

6. Neri F, Puviani L, Tsivian M, et al. Protective effect of an inhibitor of interleukin-8 (meraxin) from ischemia and reperfusion injury in a rat model of kidney transplantation. Transplant Proc 2007; 39:1771-1772.

7. Unal, D. et al. Antioxidative effects of exogenous nitric oxide versus antioxidant vitamins on renal ischemia reperfusion injury. Urol Res 2002; 30:190-194.

8. Schumer M, Colombel MC, Sawczuck IS, et al. Morphologic, biochemical and molecular evidence of apoptosis during the reperfusion phase after brief periods of renal ischemia. Am J Pathol 1992; 140:831-838.

9. Kane C J, Mitchell JA, Meng MV, et al. Laparoscopic partial nephrectomy with temporary arterial occlusion: description of technique and renal functional outcomes. Urology 2004; 63: 241–246.

10. Rubistein M, Colombo-Junior JR; Finelli A, et al. Laparoscopic partial nephrectomy for cancer: techniques and outcomes. Int Braz J Urol 2005, 31:100-104.

11. Shekarriz B, Shah G, Upadhyay J. Impact of temporary hilar clamping during laparoscopic partial nephrectomy on postoperative renal function: a prospective study. The J Urol 2004; 172:54–57.

12. Plaine LI and Hinman Jr. F. Comparison of occlusion of the renal artery with occlusion of the entire pedicle on survival and serum creatinine levels of the rabbit. J Urol 1965; 93:117–121.

13. Tracy CR, Terrel JD, Francis RP et al. Characterization of renal ischemia using dlp hyperspectral imaging: a pilot study comparing artery-only occlusion versus artery and vein occlusion. J Endourol 2010; 24:321-325.

14. Neely WA and Turner MD. The effect of arterial, venous, and arteriovenous occlusion on renal blood flow. Surg Gynecol Obstet 1959; 108:669–672.

15. Orvieto MA, Zorn KC, Mendiola F, et al. Recovery of renal function after complete renal hilar versus artery alone clamping during open and laparoscopic surgery. J Urol 2007; 177:2371–2374.

16. Jablonski P, Howden BO, Rae DA et al. An experimental model for assessment of renal recovery from warm ischemia. Transplantation 1983; 35:198-204.

17. de Souza DB, Oliveira LL, Cruz MC, et al. Laparoscopic partial nephrectomy under warm ischemia reduces the glomerular density in a pig model. J Endourol 2012, (in press) DOI:10.1089/end.2011.0412.

18. Scherle W. A simple method for volumetry of organs in quantitative stereology. Mikroskopie 1970; 26:57-60.

19. Mandarim-de-Lacerda CA. Stereological tools in biomedical research. An Acad Bras Cienc 2003; 75: 469-486.

20. Pereira LMM, Querido DL, Madeira ACM, et al. Volume-weighted mean glomerular volume in spontaneously hypertensive rats treated with different doses of spironolactone. Int Braz J Urol 2002; 28:356-362.

21. Sokal RR and Rohlf FJ. Biometry: the principles and practice of statistics in biological research. 3rd ed. New York: WH Freeman and Company, 1995, pp 240-241.

22. Gill IS, Desai MM, Kaouk JH, et al. Laparoscopic partial nephrectomy for renal tumor: duplicating open surgical techniques. J Urol 2002; 167:469–476.

23. Laven BA, Kasza KE, Rapp DE, et al. A pilot study of ice-slurry application for inducing laparoscopic renal hypothermia. BJU International, 2006; 99:166–170.

24. Shikanov S, Wille M, Large M, et al. Microparticulate ice slurry for renal hypothermia: laparoscopic partial nephrectomy in a porcine model Urology 2010; 76:1012–1016.

25. Guillonneau B, Bermúdez H, Gholami S, et al. Laparoscopic partial nephrectomy for renal tumor: single center experience comparing clamping and no clamping techniques of the renal vasculature. J Urol 2003; 169:483–486.26. Formiga CC, Mitre AI, Castilho LN, et al. Comparison of clamping modalities in a rabbit model of normothermic renal ischemia. J Endourol 2011; 25:1787-1791.

27. Ysebaert DK, De Greef KE, Vercauteren SR, et al. Identification and kinetics of leukocytes after severe ischaemia/reperfusion renal injury. Nephrol Dial Transplant 2000; 15:1562-1574.

28. Benchimol de Souza D, Silva D, Marinho Costa Silva C, et al. Effects of immobilization stress on kidneys of Wistar male rats: A morphometrical and stereological analysis. Kidney Blood Press Res 2011; 34:424-429.

29. Nyengaard JR. Stereologic methods and their application in kidney research. J Am Soc Nephrol 1999; 10:1100-1123.

30. Gong M, Zorn KC, OrvietoMA, et al. Artery-only occlusion may provide superior renal preservation during laparoscopic partial nephrectomy. Urology 2008; 72:843– 846.

Table 1. Stereological data of kidneys from animals submitted to Artery only clamping, Artery and vein clamping and Sham surgery

	Artery only clamping		Artery and vein clamping		Sham	
	right	left	Right	left	right	left
MGV	1.06 (± 0.16)	1.07 (± 0.19)	1.04 (± 0.12)	0.97 (± 0.13)	1.07 (± 0.09)	1.1 (± 0.16)
Vv[glom]	16.48 (± 3.28)	14.65 (± 2.95)	18.6 (± 2.82)	12.02 (± 5.23)	16.09 (± 5.77)	16.03 (± 4.55)
Nv[glom]	15.72 (± 2.62)	13.89 (± 3.01)	17.98 (± 3.2)	12.34 (± 4.92)	15.1 (± 5.72)	14.75 (± 4.12)

Data expressed as mean ± standard deviation. MGV – Mean glomerular volume, Vv[glom] – Glomerular volume density, Nv[glom] - number of glomeruli per cubic millimeter of renal cortex

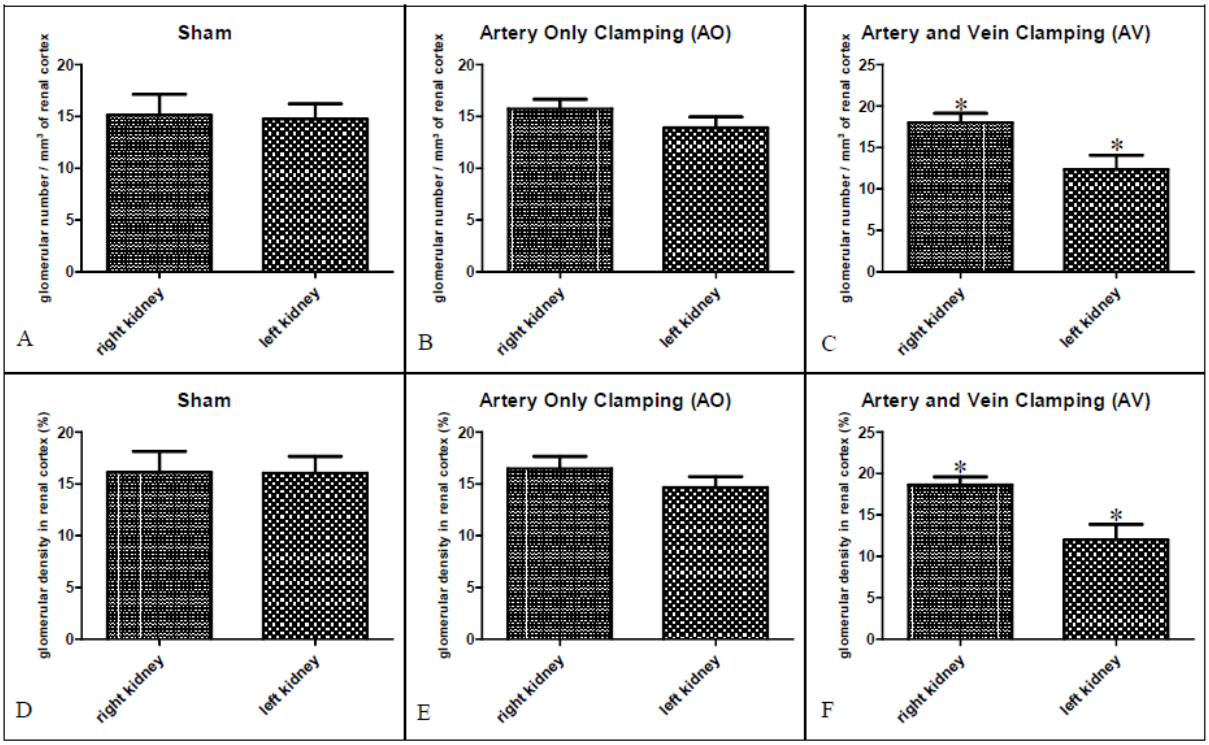

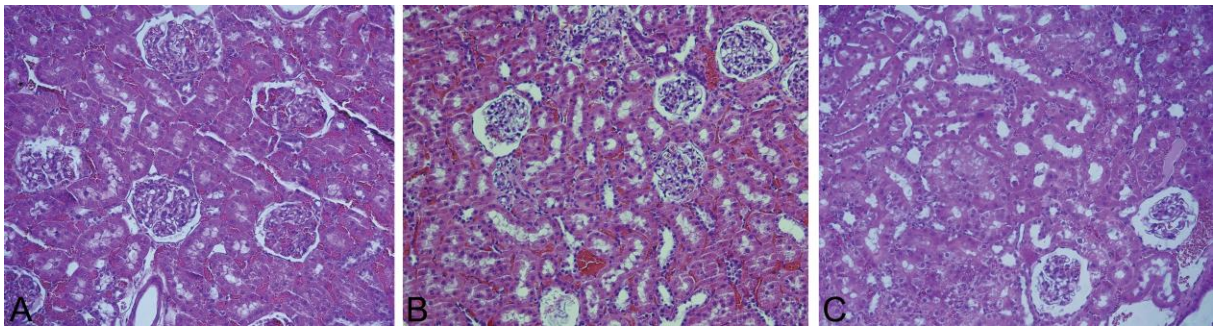

LEGENDS

Figure 1: Number of glomeruli per mm^3 of renal cortex in both right and left kidneys from group Sham (A), group Artery Only clamping (B) and group Artery and Vein clamping (C). Glomerular density in renal cortex in both right and left kidneys from group Sham (D), group Artery Only clamping (E) and group Artery and Vein clamping (F). The results are expressed as mean and standard error. *$p < 0.05$.

Figure 2: Photomicrographs of renal cortex of left kidneys from group Sham (A), group Artery Only clamping (B) and group Artery and Vein clamping (C). Note a reduced number of glomeruli in group Artery and Vein clamping when compared to group Sham and group Artery Only clamping. HE, X200.

ANEXO A – Aprovação da Comissão de Ética para o cuidado e uso de animais experimentais

UNIVERSIDADE DO ESTADO DO RIO DE JANEIRO
INSTITUTO DE BIOLOGIA ROBERTO ALCANTARA GOMES

COMISSÃO DE ÉTICA PARA O CUIDADO E USO DE ANIMAIS EXPERIMENTAIS

C E R T I F I C A D O

Certificamos que o Protocolo nº **CEUA/012/2012** sobre **"Avaliação do parênquima renal após isquemia-reperfusão e efeito protetor da L-arginina em ratos"**, sob a responsabilidade de **Francisco José Barcellos Sampaio,** está de acordo com os Princípios Éticos na Experimentação Animal adotados pelo Colégio Brasileiro de Experimentação Animal (COBEA), tendo sido aprovado pela Comissão de Ética Para o Cuidado e Uso de Animais Experimentais do Instituto de Biologia Roberto Alcântara Gomes da UERJ (CEA), em **08/03/2012.** Este certificado expira em **08/03/2016.**

Rio de Janeiro, 08 de Março de 2012.

Profa. Patricia Cristina Lisboa
CEA/IBRAG/UERJ
Profª Dra. Patrícia Cristina Lisboa da Silva
Profª Adj. do Depto. Ciências Fisiológicas / IBRAG / UERJ
Matrícula 34765-8

Prof. Israel Felzenszwalb
CEA/IBRAG/UERJ
Israel Felzenszwalb
Matr. 2887-8

/.ass

☎ (21) 2587-6488 / 2587-6109 - Fax (21) 2284-9748
biologia@uerj.br